# 대한소화기항암학회 학술집담회

서울대학교병원 소화기내과
김재환, 안동원, 윤원재, 류지곤, 김용태, 윤용범

# Case Presentation

- F/62
- Chief complaint
  - Jaundice and itching sense (since 1 week ago)
- Present illness
  - 이전 건강하던 환자가 2주전부터 시작된 상기도 감염 증상으로 인근 병원 방문하여 약 처방 받아 복용하던 중 1주전부터 황달과 소양증세 발생하여 내원
- PMHx & SHx
  - No PMHx & 주부, Alcohol (-)/Smoking (-)
- PE & ROS
  - Icteric, palpable liver (+), 5Kg loss/1mo
- Lab
  - LFT 82 mg/dL– 6.9/3.5 g/dL – 8.8 mg/dL – 290IU/L - 19/17 IU/L
  - CEA 35.6 ng/mL, CA 19-9 718 U/mL
  - HBsAg (-),  anti-HCV (-)

# Abd US

FR 35Hz
S1
2D
45%
C 55
P Med
Gen
M2
14

FR 35Hz
S1
2D
45%
C 55
P Med
Gen
M2
Dist 3.29 cm
14

S1
2D
45%
C 55
P Med
Gen
14

S1
2D
37%
Gen
9.0
Dist 2.01 cm

# Abd CT - initial

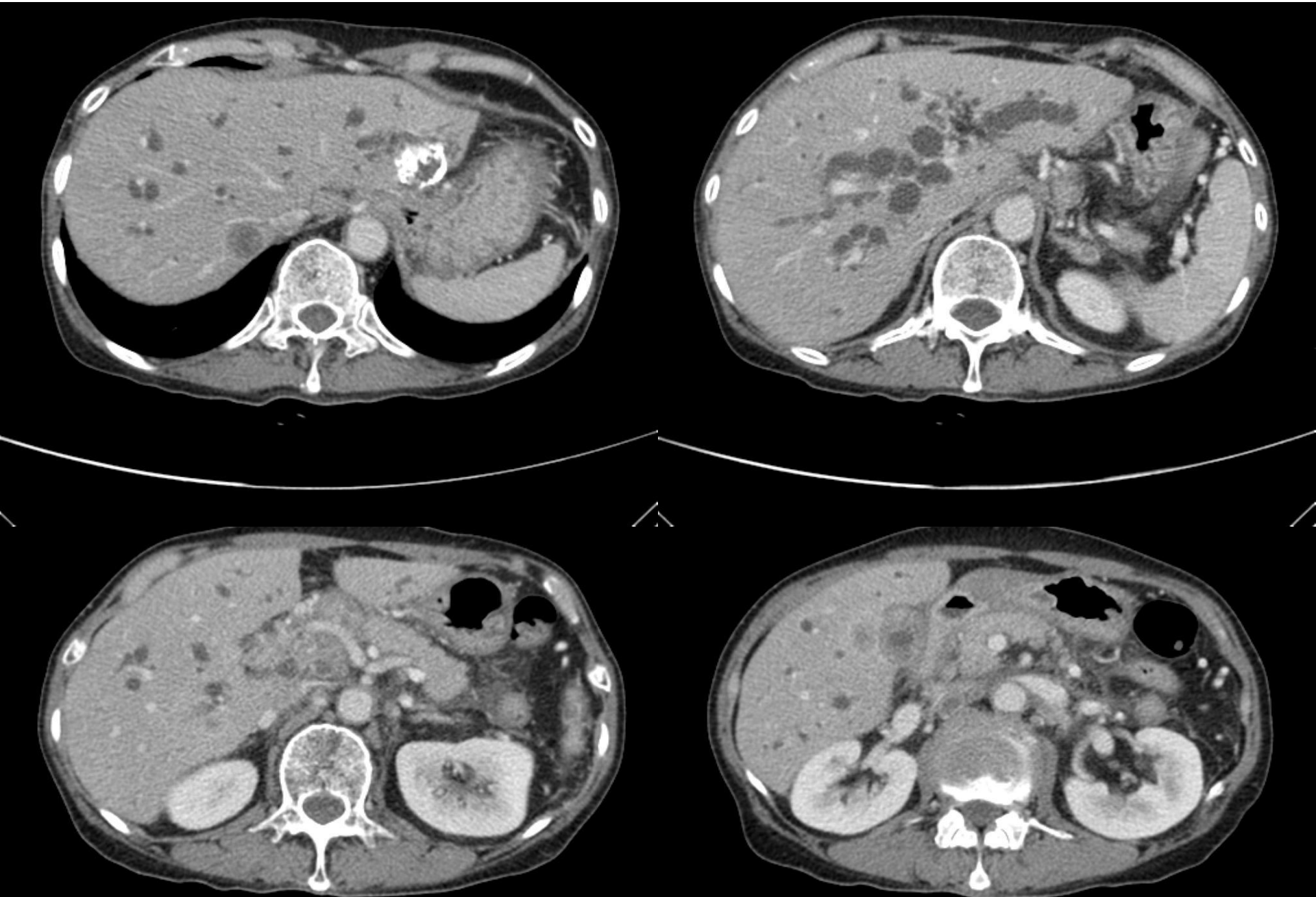

# Assessment and Plan

- Assessment
  - r/o GB cancer with multiple metastasis (ECOG score 1)
    (extensive lymphadenopathy, liver,  left adrenal gland, omental seeding)
  - Jaundice
  - Gallbladder stone
  - Cold Liver Abscess

- Plan
  - Biliary drainage
  - Tissue confirmation
  - Palliative chemotherapy

# ERCP

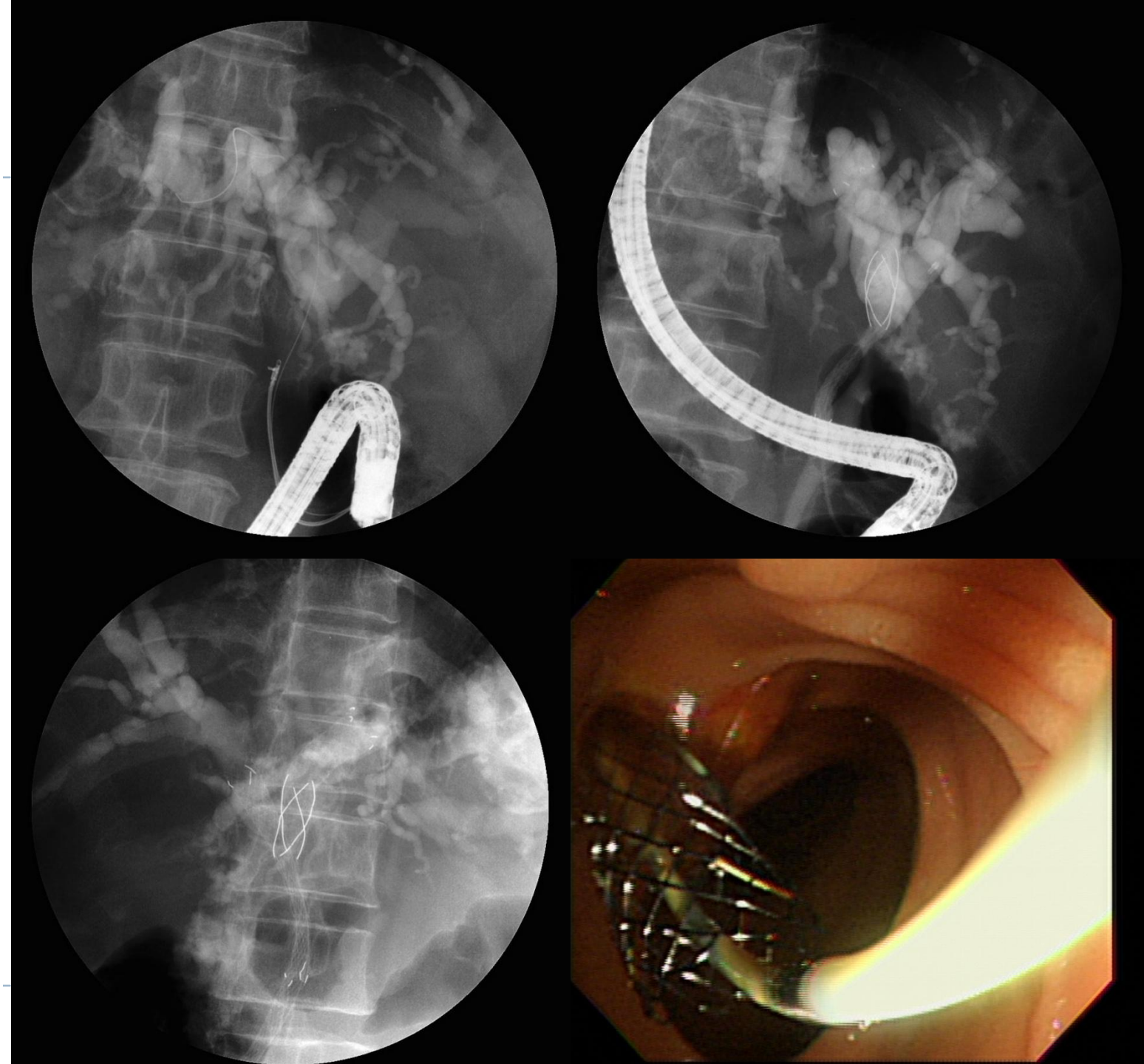

# Brush cytology and biopsy

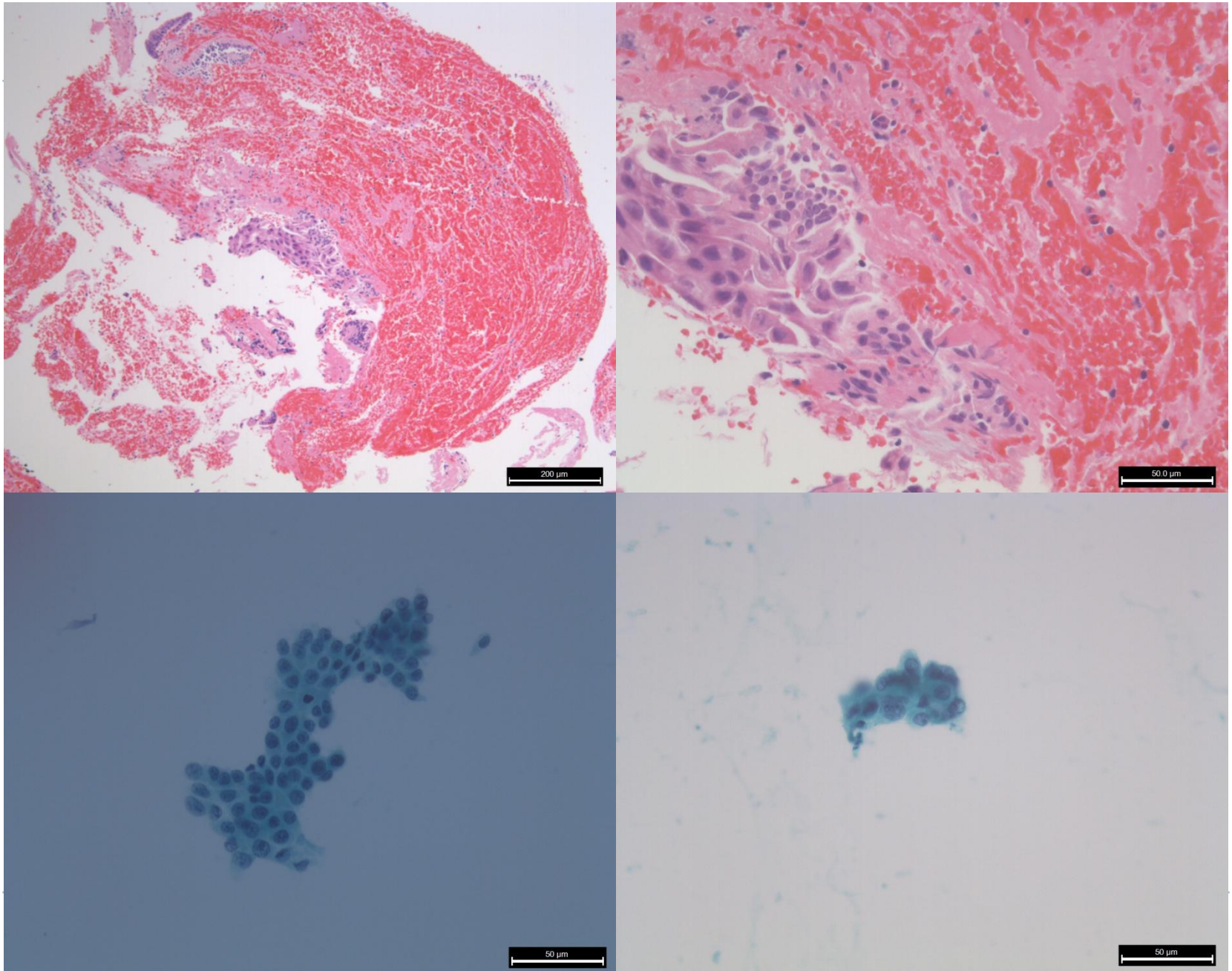

# ER vist (3 days later discharge)

- Chief complaint
  - Rt. facial numbness
- Neurologic exam
  - MSE - alert consciousness / intact orientation
  - CNE
    L/R : both prompt / isocoric , EOM : full range (+)
    VFD (-) diplopia(-) , 오른쪽 얼굴의 감각저하
    symmetric facial expression , Dysarthria(-)
    T/D(-) U/D(-) SPE : symmetric
  - MOTOR
    V/V
    V/V
  - SENSORY - symmetric and intact
  - CEREBELLAR FUNCTION TEST
    : FTF(-) FTN(-)
  - Gait : normal

# Brain MRI

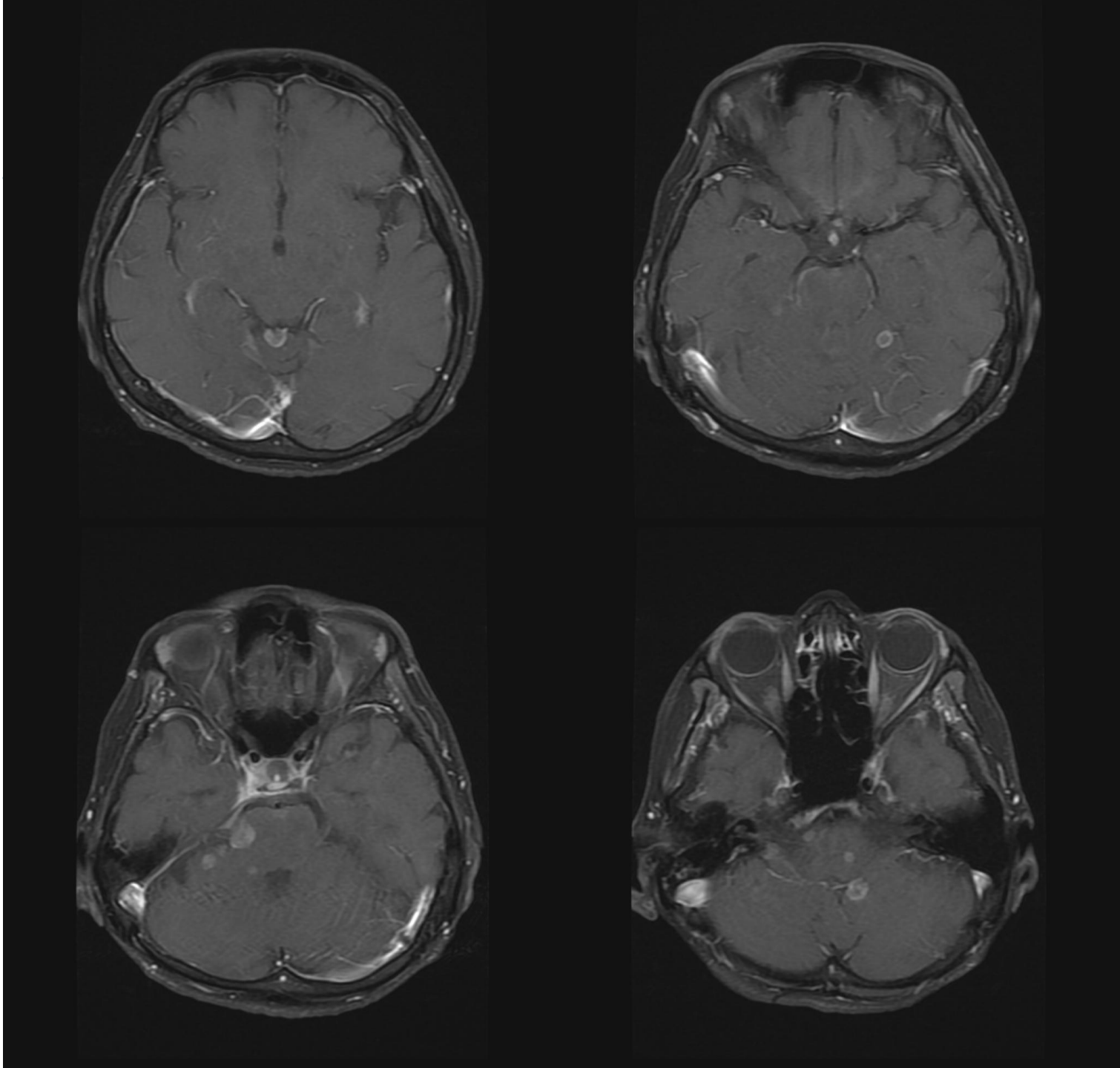

# Treatment

- Whole Brain RT (300Gy/2week)
- Palliative Chemotherapy
  - Gemcitabine + TS-1 q21d
    - Gemcitabine 1400mg miv on day 1 & 8 (1000mg/$m^2$)
    - TS-1 40mg bid daily on days 1-14 (60mg/$m^2$)

# Abd CT – follow up

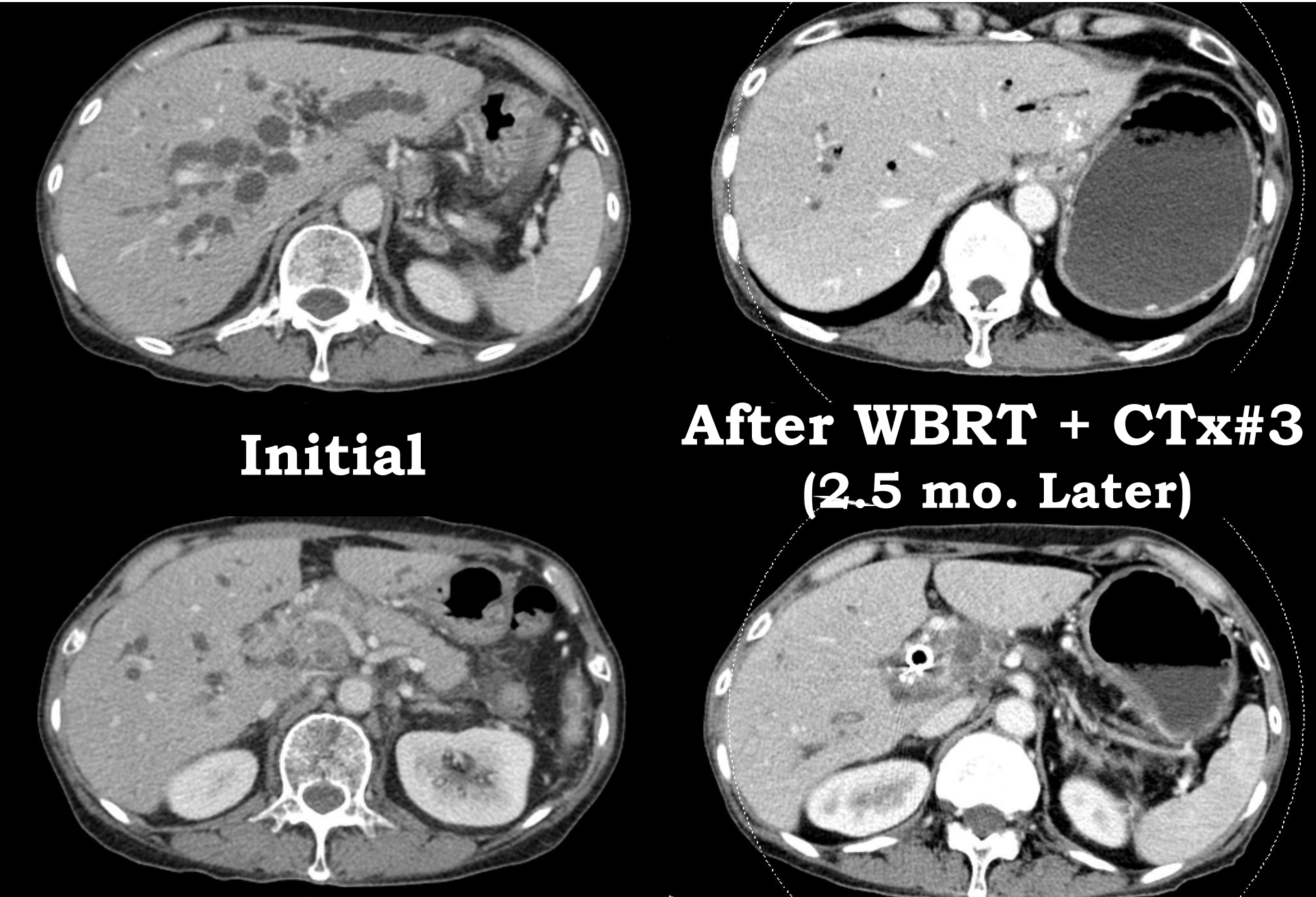

# Brain MRI – follow up

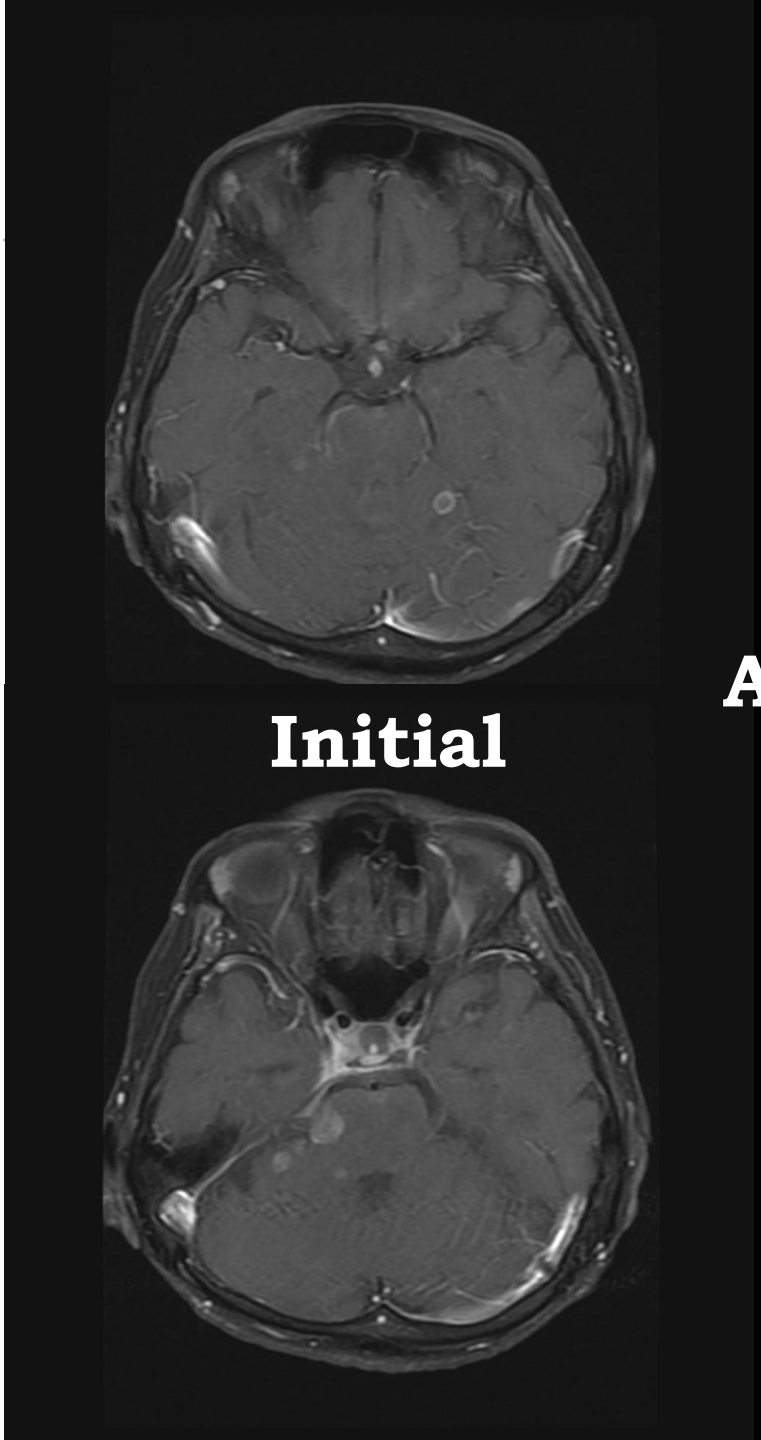


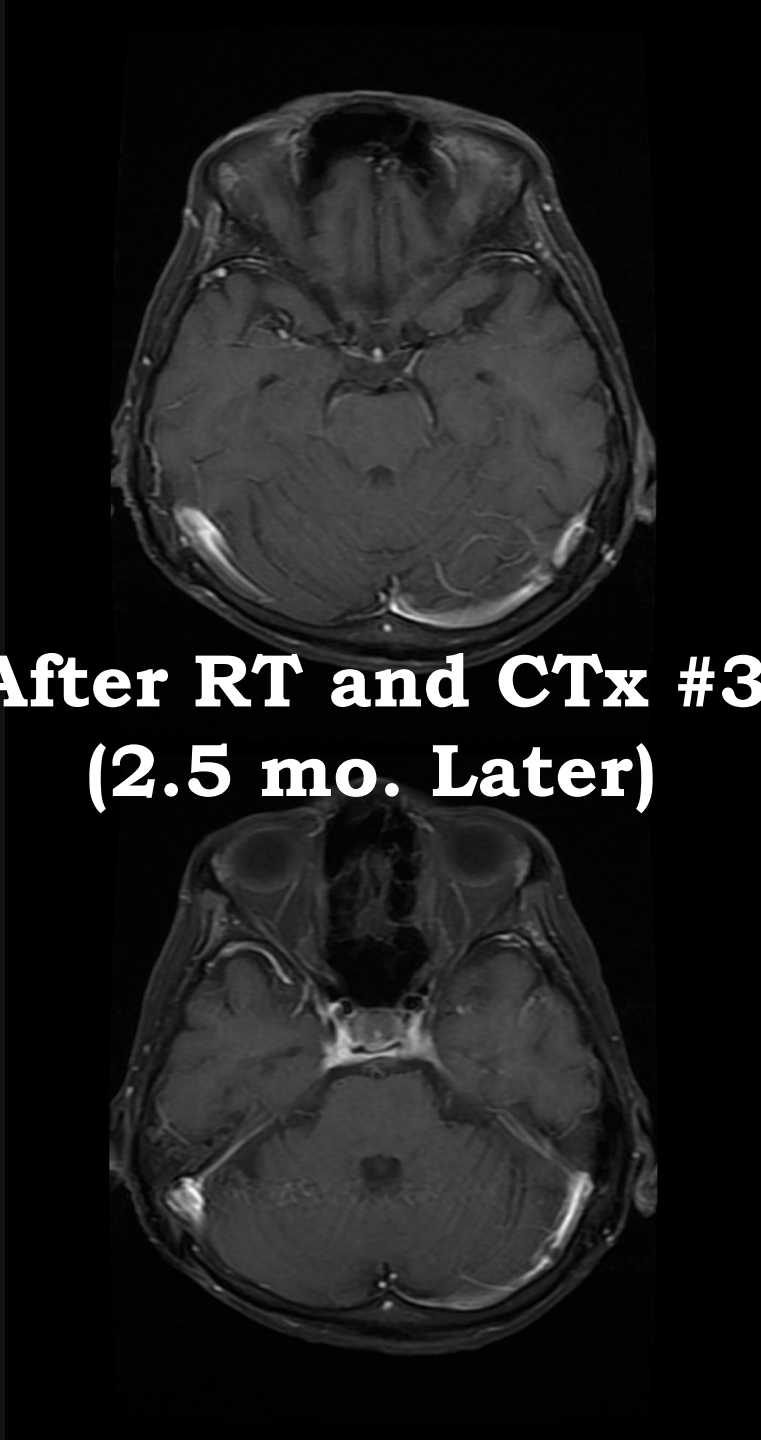

# Hospital Course

- 2009.9 develop — Jaundice and itching sense
  r/o GB cancer with multiple metastasis
- 2009.9.28 — Metal stent insertion
- 2009.9.29 — Cytology (+) for malignant cells
  Confirmed GB cancer
- 2009.10.7-20 — WBRT to brain metastasis
- 2009.10.22 start — Gemcitabine + TS 1 #1
- 2009.12.3 — Gemcitabine + TS 1 #3 ; stable disease

# Abd CT – follow up

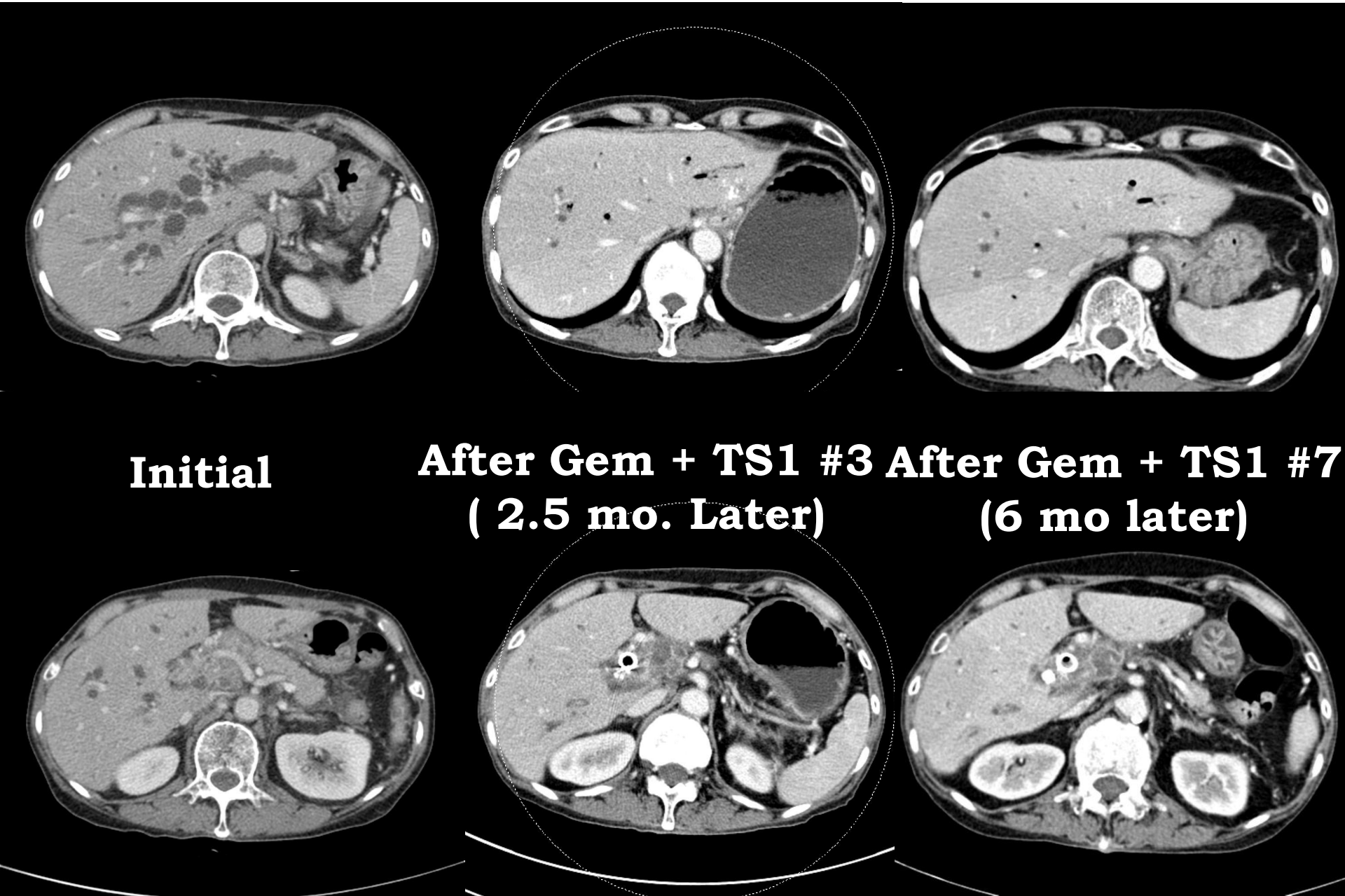

# Hospital Course

- 2009.9 Jaundice and itching sense develop
  r/o GB cancer with multiple metastasis
- 2009.9.28 Metal stent insertion
- 2009.9.29 Cytology (+) for malignant cells
  Confirmed GB cancer
- 2009.10.7 -20 WBRT to brain metastasis
- 2009.10.22 Gemcitabine + TS 1 #1 start
- 2009.12.3 Gemcitabine + TS 1 #3 ; stable disease

# Tumor Markers

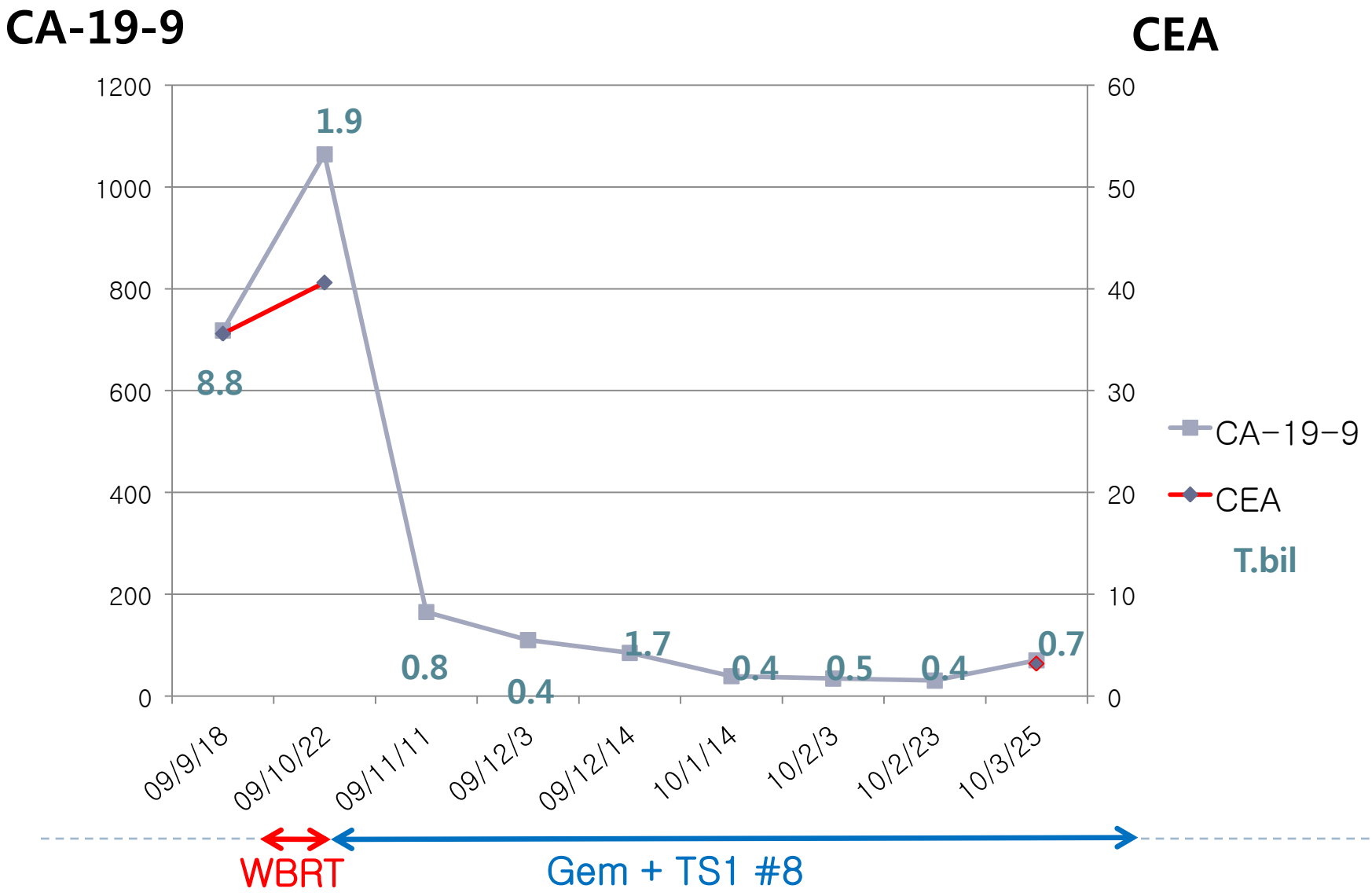

# GB cancer with CNS metastasis

- A diffuse metastatic leptomeningeal carcinomatosis from gallbladder cancer; case report.
  - No Shinkei Geka. 1991 Nov;19(11):1091-5.
- Central nervous system metastasis from gallbladder carcinoma mimicking a meningioma. Case illustration.
  - J Neurosurg. 1999 Dec;91(6):1059.
- Gallbladder carcinoma cells in cerebrospinal fluid as the first manifestation of  a tumor. A case report.
  - Acta Cytol. 2003 Nov-Dec;47(6):1087-90.
- Gall bladder carcinoma: stroke as first manifestation.
  - Indian J Gastroenterol. 2006 Nov-Dec;25(6):316.

# GB cancer with CNS metastasis

- Central nervous system metastasis from gallbladder carcinoma-case report.
  - Neurol Med Chir (Tokyo). 1991 Dec;31(12):782-6.

Table 1 Reported cases of CNS metastases from gallbladder carcinoma

| Case No. | Author (Year) | Age/ Sex | Symptoms | CNS metastases | Other metastases | Outcome | Survival from admission |
|---|---|---|---|---|---|---|---|
| 1 | Krasting (1906)[14] | 59/F | — | cerebellum (multiple) | liver, lung, LN, peritoneum | died | — |
| 2 | | 69/F | — | dura | peritoneum, pleura | died | — |
| 3 | Cappell and Tudhope (1933)[5] | 50/F | rt hemiplegia, aphasia | lt internal jugular vein, sigmoid sinus | peritoneum, LN | died | — |
| 4 | Bagnoli and Pagni (1951)[2] | 40/F | — | dura | liver, stomach, LN | died | — |
| 5 | Tazaki and Ohsaka (1967)[26] | 72/M | lt hemiparesis | rt frontal lobe, lt basal ganglia | adrenal gland, LN, pancreas | died | 72 days |
| 6 | Vaittinen (1977)[28] | 52/M | — | rt parietal lobe, lt cerebellum | LN | died | — |
| 7 | Nonomura *et al.* (1980)[15] | 52/F | headache, bulbar palsy | cerebellum | lung, ovary, LN, bone, stomach | died | 84 days |
| 8 | Saito *et al.* (1981)[23] | 71/F | headache, blurred vision | meninges | ovary, bladder, LN | died | 69 days |
| 9 | Smith *et al.* (1983)[23] | 58/F | headache | SSS, cavernous sinus | liver, pancreas, LN | died | 10 days |
| 10 | Present case | 68/F | convulsion | lt frontal lobe | — | alive | 4 years |

LN: lymph node, SSS: superior sagittal sinus.

  - Large brain metastasis series ; GB carcinoma was the primary site in less than 0.5% of all cases.
  - The incidence of CNS metastases from GB carcinoma is approximately 2%.