

Session III

Secondary Achalasia of Gastric Linitis Plastica

Sun Hwa Kim, In Kyung Yoo, Won Hee Kim, Sung Pyo Hong, Joo Young Cho

Division of Digestive Disease, Bundang Cha Medical Center, Seongnam, Korea

1. Case presentation

2018년 5월 타병원에서 Achalasia로 풍선확장술 중 발생한 식도 과열로 인한 종격동 농양으로 수술을 받은 분으로, 본원 내원 3개월 전부터 발생한 흉통 및 삼킴곤란으로 내원하여 POEM 시행받고, 이후 시행한 위 조직검사서 Borrmann type 4 AGC 진단받고 항암치료 및 stent insertion 시행하였다.

2. Diagnosis

- Secondary Achalasia of Gastric Linitis Plastica

3. Therapy and Clinical course

- POEM, Chemotherapy

4. Conclusion

Achalasia 환자를 볼 때 secondary achalasia 가능성을 항상 염두에 두어야 한다.

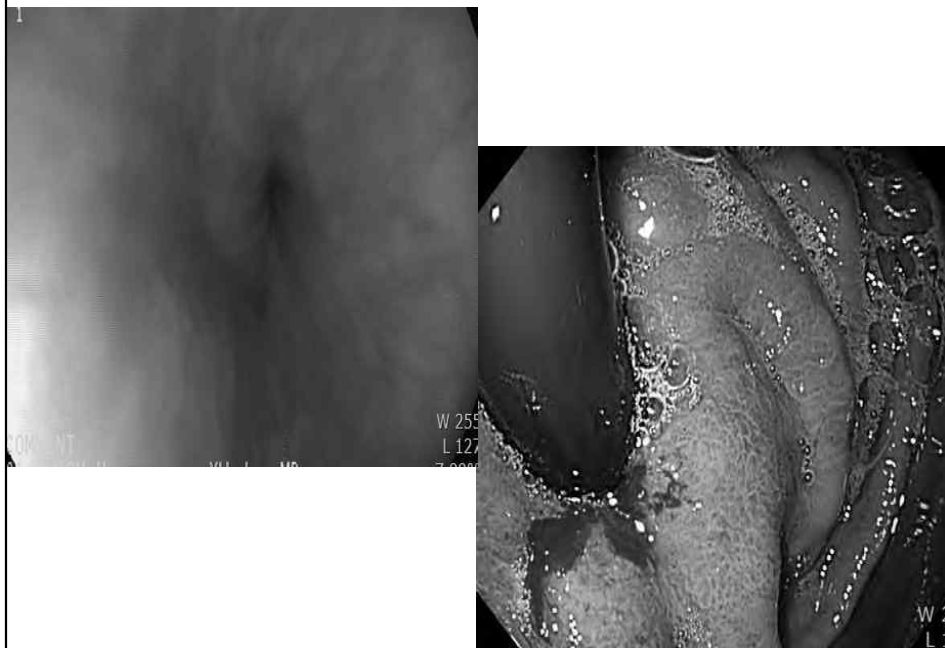
Key words: Achalasia, Gastric linitis plastica, Advanced gastric cancer

Case

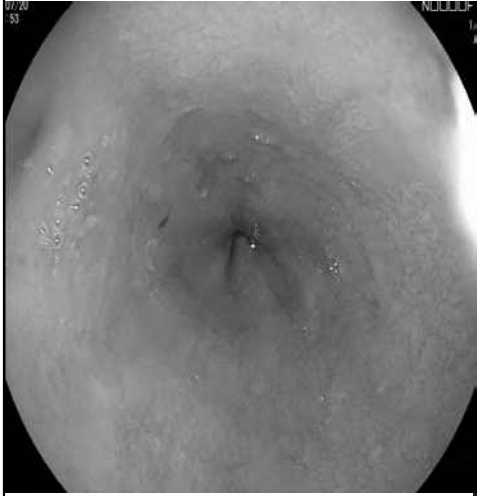
- 43/M
- C.C: **흉통, 삼킴곤란**
- P.I: 2018년 5월 타병원에서 Achalasia로 **풍선확장술**
중 발생한 식도 파열로 인한 증격동 농양으로 수술을
받은 분으로, 본원 내원 3개월 전부터 발생한 흉통 및
삼킴곤란으로 내원



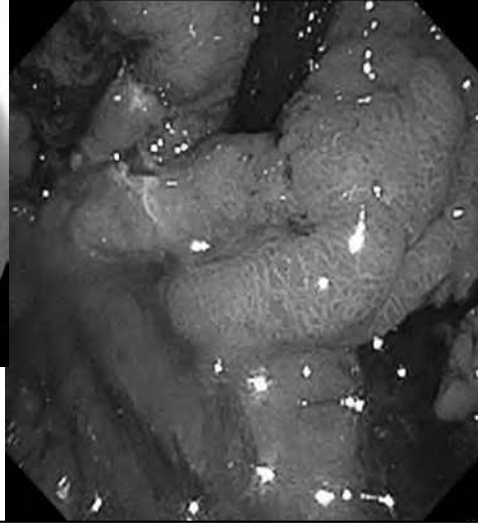
EGD



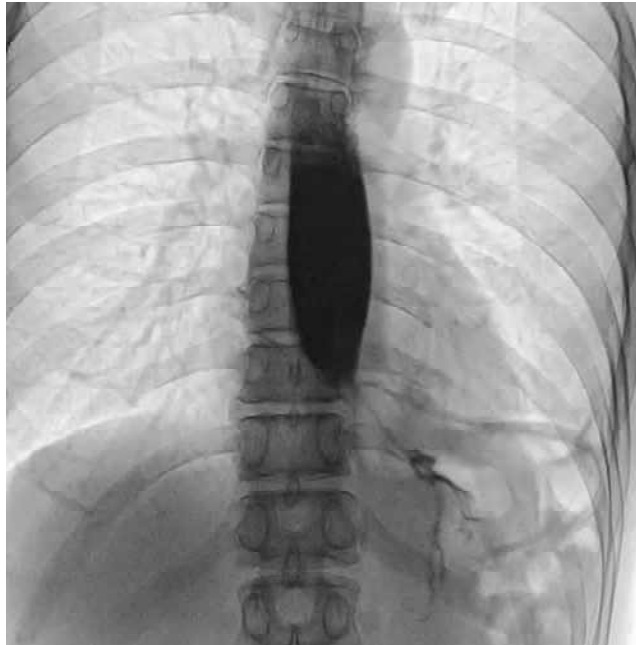
EGD & bx

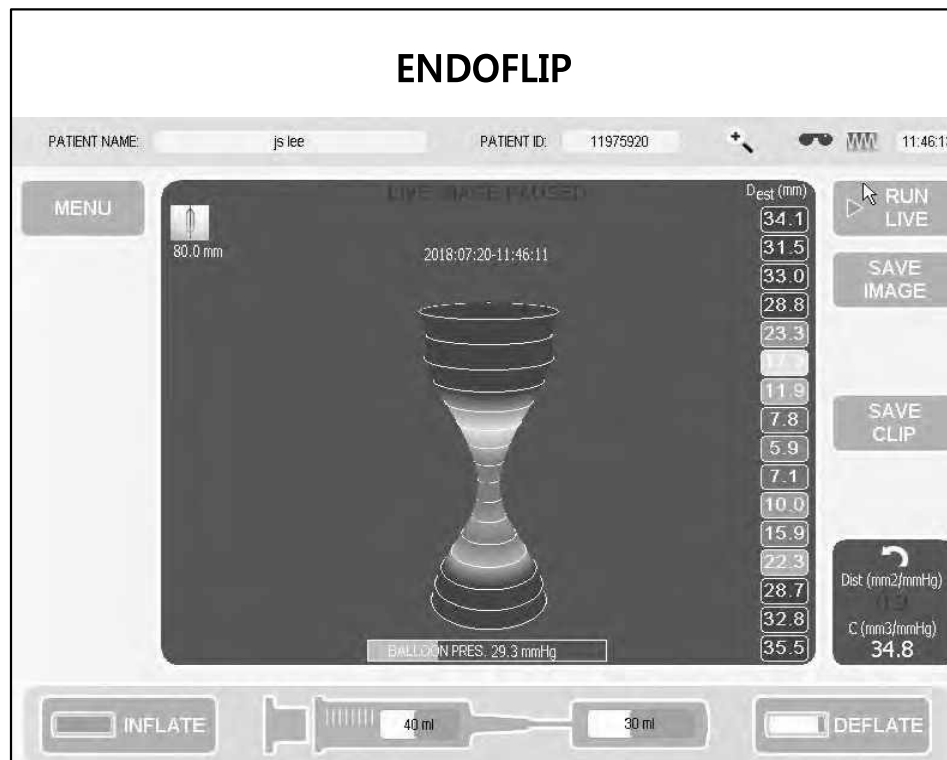

Stomach bx: chronic gastritis




Esophagography





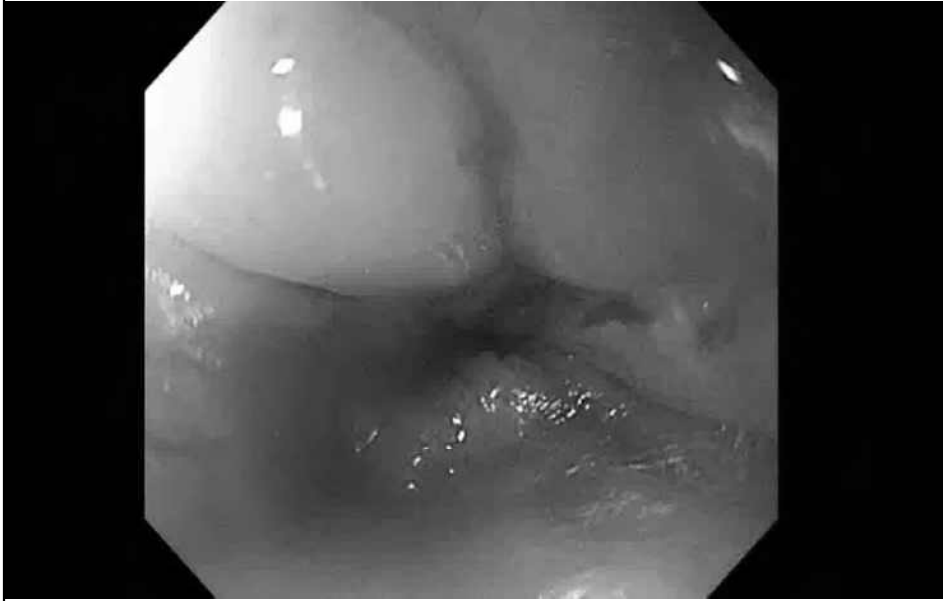HRM



- LES pressure (62 mmHg)
- Residual pressure (37 mmHg)
→ impaired LES relaxation
- IRP (43 mmHg)
- Contractions of esophageal body were peristaltic, but 70% were failed, distal pressurization

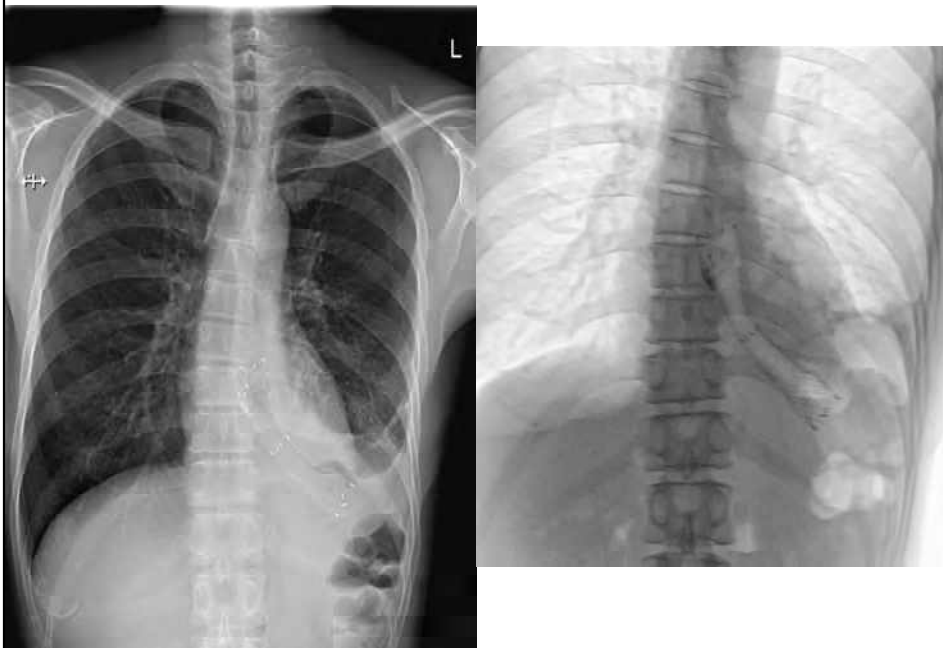
Impression: Achalasia

OPEN POEM + STENT

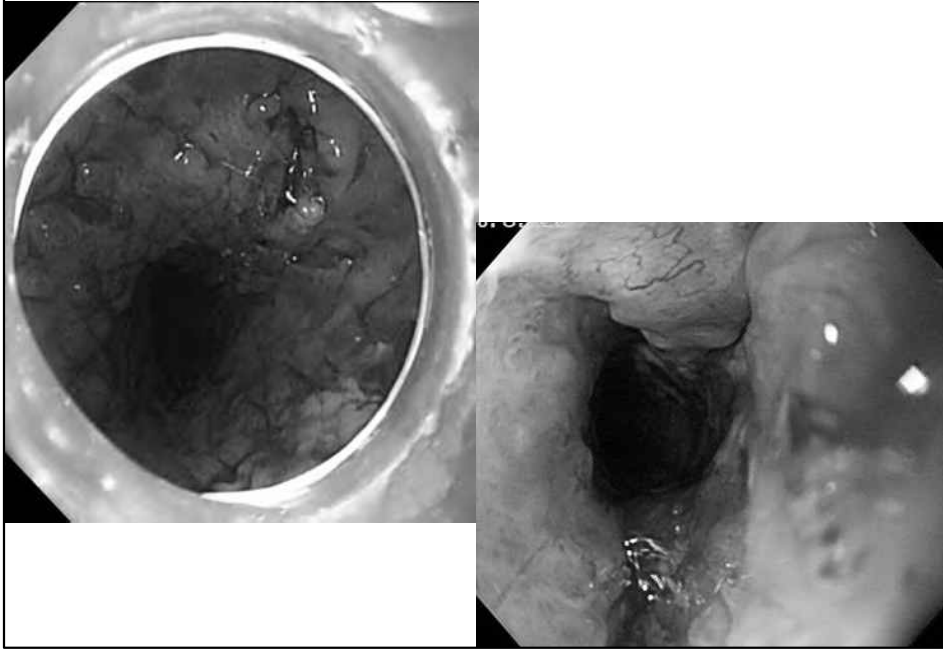


Esophagogastric junction stricture

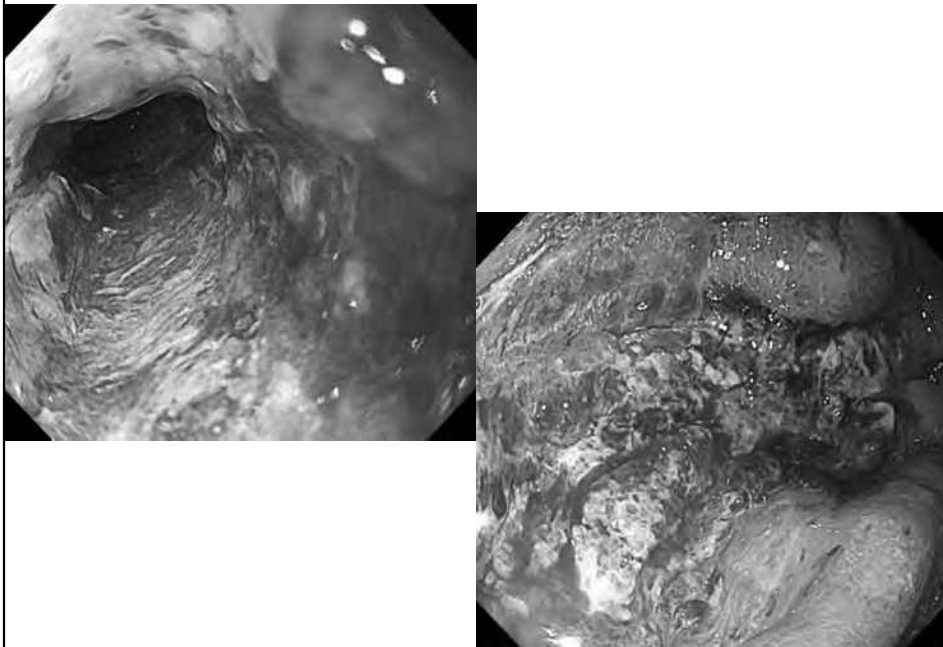
Stent insertion state



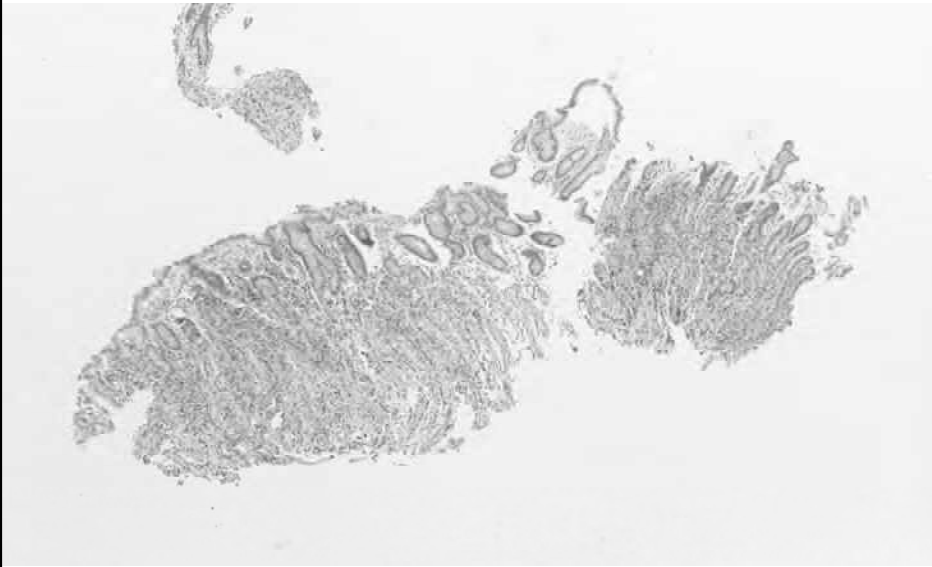
Stent removal (POD #40)



Follow up EGD bx

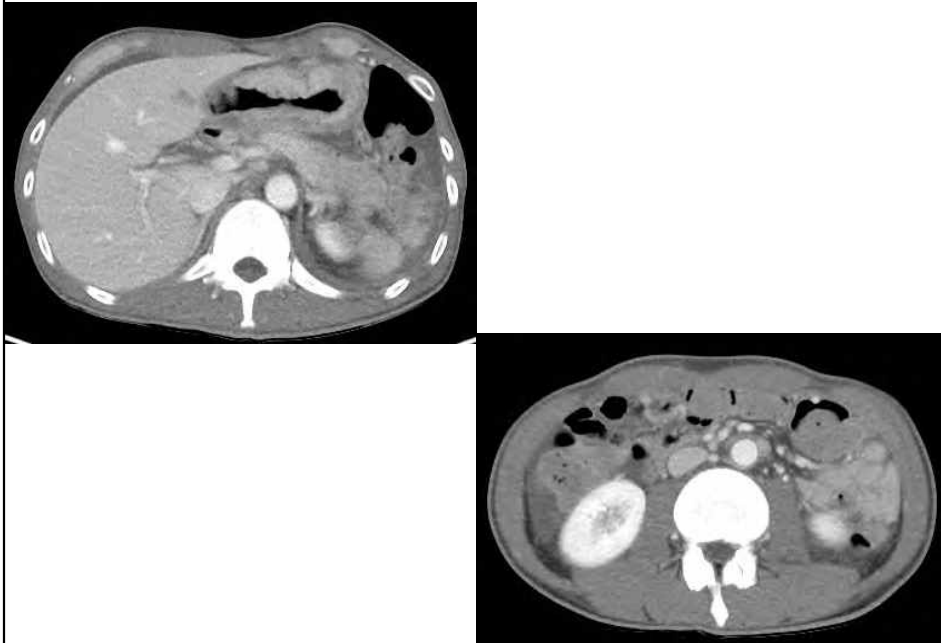

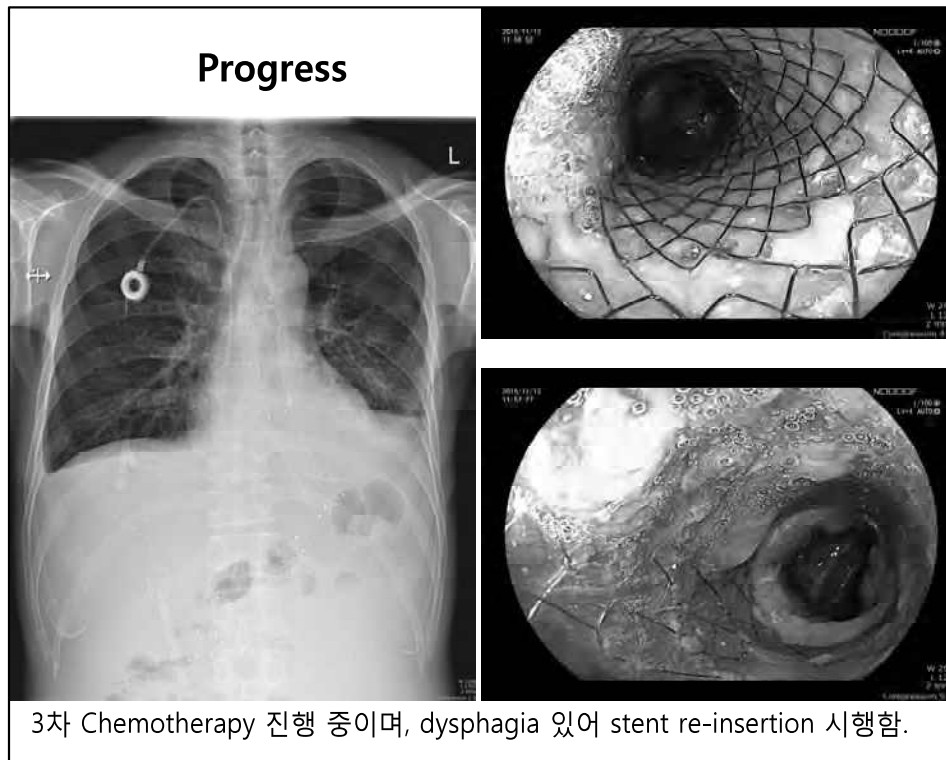
Pathology



Stomach bx: adenocarcinoma, poorly differentiated

Abdomen CT





memo

MEMO