Session I

# A Case of Peutz-jegher Syndrome with Pancreatic Cancer

**Sung Yong Han, Dong Uk Kim, Dong Hoon Baek, Geun Am Song**

*Department of Internal Medicine, Pusan National University School of Medicine, Busan, Korea*

## 1. Case presentation

58세 남자가 2주 전부터 시작된 소화불량 및 1주일 전부터 시작된 복부 팽만감을 주소로 내원하였다. 타병원 CT에서 r/o CP가 확인되어 본원에 내원하여 PET-CT 및 CT 검사를 시행하였고, 통한 조직검사를 하였다. 환자는 4년 전 십이지장에 huge polyp이 확인되어, ESD 통한 제거를 하였고, harmatomatous polyp으로 진단, 그리고 대장에서 multiple harmatomatous polyp을 제거한 병력이 있었다.

## 2. Diagnosis

조직검체는 CK7 (+), CK20 (-), CAX-2 (+), Smad4 (focal loss of expression)이 확인된 metastatic poorly differentiated adenocarcinoma with signet ring cell feature로 확인되었으며, IHC를 바탕으로 pancreatobiliary tract origin으로 판단하였다. 또한 CT 및 PET-CT에서 primary mass가 pancreas tail로 판단되어 최종 진단은 pancreatic ca. /c CP로 진단하였다.

## 3. Therapy and Clinical course

수술적 치료가 힘든 case로서 항암치료를 시작하였으나, gemcitabine - nab-paclitaxel으로 1 cycle 치료를 받은 이후 환자는 퇴원하였고, 이후 follow up loss 되어 추가적인 정보는 확인할 수 없었다.

## 4. Conclusion

Peutz-jegher syndrome은 드문 질환이며, 이의 악성화 발생 위험도는 상당히 높은 것으로 알려져 있다. PJS 진단된 이후 follow up loss된 이후 advanced pancreatic cancer로 진단한 증례를 보고한다.

**Key Words**: peutz-jegher syndrome, Pancreatic cancer

## REFERENCES

1. Giardiello FM, Brensinger JD, Tersmette AC, Goodman SN, Petersen GM, Booker SV & Offerhaus JA. Very high risk of cancer in familial Peutz-Jeghers syndrome. Gastroenterology 2000;119(6):1447-1453. NCCN

clinical practive guidelines in oncology: Neuroendocrine tumor (ver 3.2017)
2. Resta N, Pierannunzio D, Lenato GM, Stella A, Capocaccia R, Bagnulo R, & Sabbà C. Cancer risk associated with STK11/LKB1 germline mutations in Peutz-Jeghers syndrome patients: Results of an Italian multicenter study. DigestiveandLiverDisease 2013;45(7):606-611.

## M/58

**C.C)** Abdominal distension

**P.I)** 내원 2주일 전부터 소화불량증상이 있었으며, 1주일전부터 복부 팽만감이 있어 타병원에서 시행한 CT에서 r/o CP 소견으로 내원

**P.Hx)** HT / DM / Hepa / Tbc - / + / - / -

Peutz-jegher synd.

**S.Hx)** smoking: current smoker (60 pack-years)

alcohol: 소주 2병/회, 5회/주

## 2014.06.24 EGD

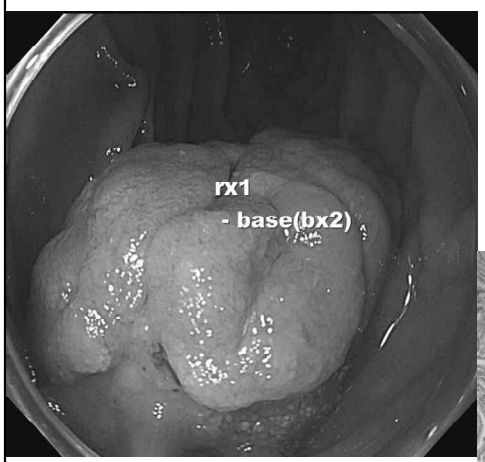


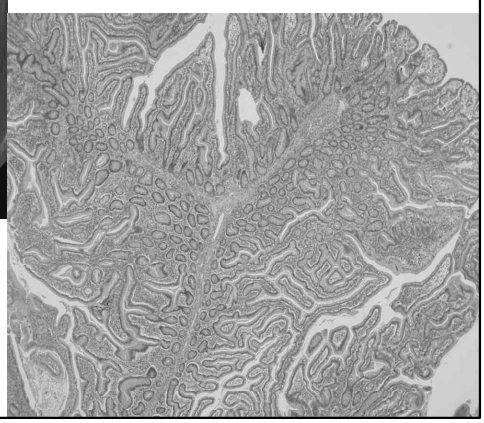

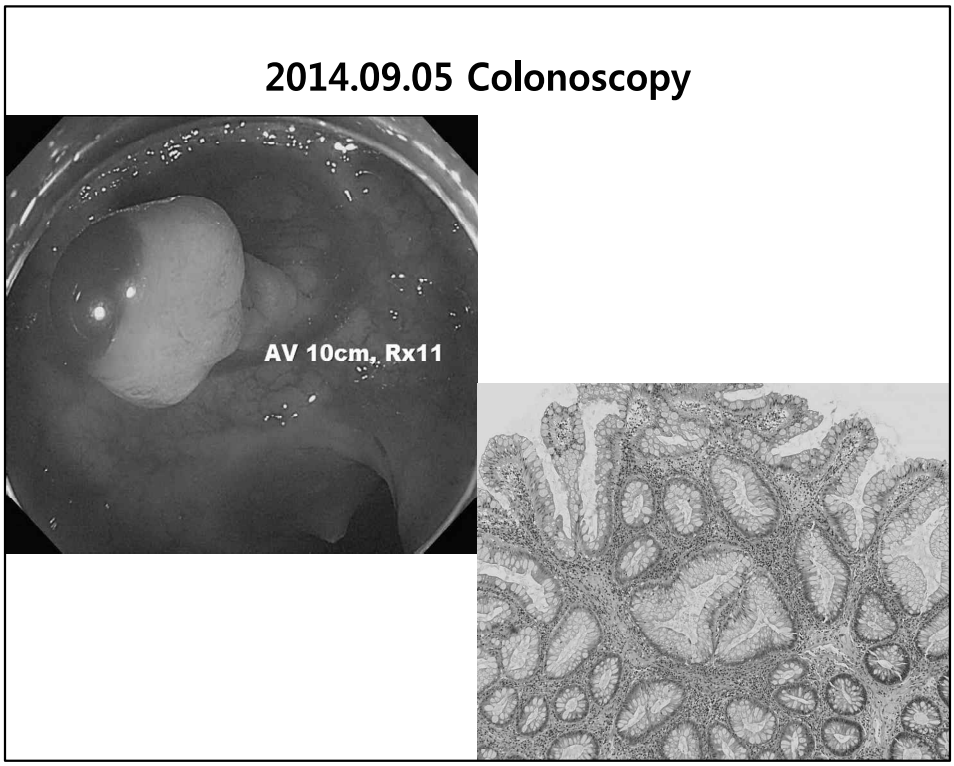
2014.09.05 Colonoscopy
AV 10cm, Rx11

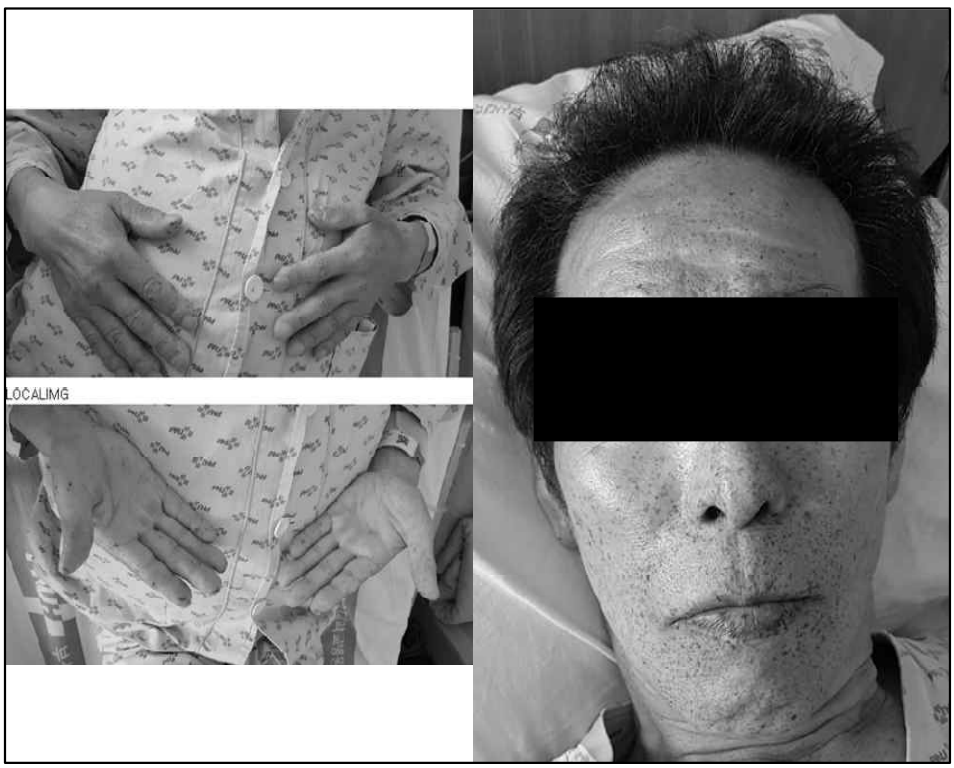
LOCALIMG

## Review of System

**[Constitutional systems]**
General weakness/Fatigue/**Weight loss**/Weight gain/Chilling/Fever (-/-/**4 kg/month** /-/-/-)

**[HEENT]**
Headache/Dizziness/Sore throat (-/-/-)

**[Cadiovascular & Respiratory]**
Chest pain/Dyspnea/Palpitation (-/-/-) Cough/Sputum/Wheeze/Hemoptysis (-/-/-/-)

**[Gastrointestinal]**
**Anorexia**/Nausea/Vomiting/Diarrhea/Constipation (+/-/-/-/-) Abdominal pain (-)

**[Genitourinary]**
Dysuria/Frequency/Urgency/Hematuria (-/-/-/-)

**[Musculoskeletal]**
Arthralgia/Joint swelling/Stiffness (-/-/-)

## PHYSICAL EXAMINATION

- **GA / GC**
  - Not ill appearance
  - good condition
- **HEENT**
  - Not anemic conjunctivae
  - AnIcteric sclera
  - Not dehydrated tongue
  - Not engorged neck v.
  - No CLN, SCLN enlargement
- **Chest**
  - CBS /s r
  - RHB /s m
- **Abdomen**
  - **distended**
  - Whole abd. T/RT -/-
  - Audible BS
- **Extremities**
  - No Pitting edema

## Lab finding (18.04.18)

| CBC | | |
|---|---|---|
| **WBC** | 9,060 | /mm$^3$ |
| **neutrophil** | 83.5 | % |
| **Hb** | 13.5 | g/dL |
| **PLT** | 512 | 10$^3$/mm$^3$ |

| | | |
|---|---|---|
| **Amy/Lip** | 50.2/46.7 | IU/L |
| **GGT** | 17 | IU/L |
| **CRP** | **4.70** | mg/dL |
| **CA19-9 /CEA** | 6.70 **/34.1** | U/mL /ng/mL |

| Biochemistry | | |
|---|---|---|
| **AST/ALT** | 17/13 | IU/L |
| **ALP/LDH** | 67/211 | IU/L |
| **TB/DB** | 0.21/0.10 | mg/Dl |
| **TP/Alb** | 5.0/3.2 | gm/dL |
| **BUN/Cr** | 10.9/0.62 | gm/dL |
| **TC/UA** | 119/4.5 | gm/dL |
| **Ca/P** | 8.1/4.2 | gm/dL |
| **Na/K** | 135.9/3.68 | mEq/L |

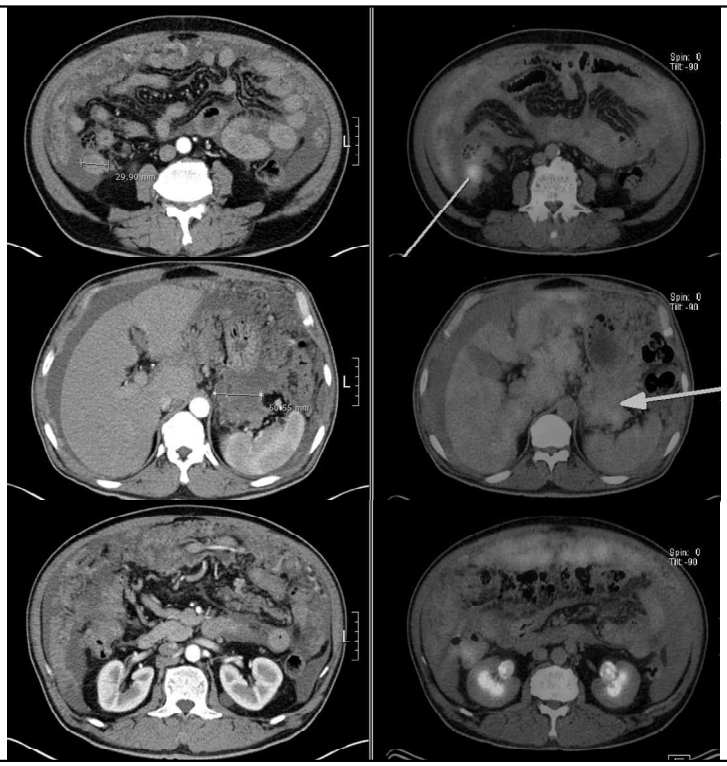

## Biopsy result

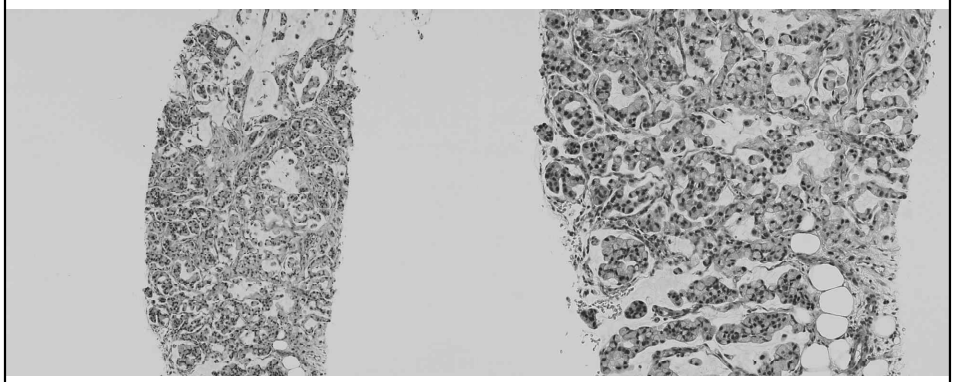

Omentum, biopsy :
Metastatic poorly differentiated adenocarcinoma with signet ring cell feature.

CK7(+), CK20(-), CEA(+), CDX-2(+), Smad4 (focal loss of expression)
: based on clinical history and immunohistochemistry result, suggestive of metastatic adenocarcinoma origin from pancreaticobiliary tract.



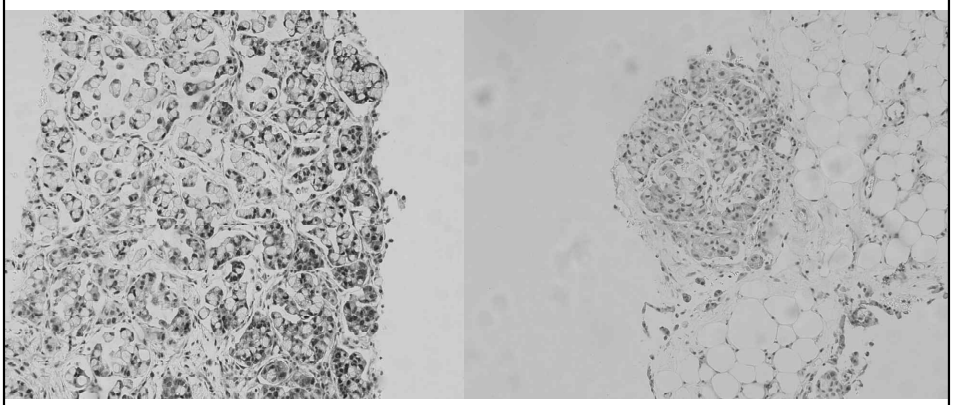

**Smad4 : focal loss of expression**

## Case Review

**Peutz-jegher synd.**

## Peutz-jegher syndrome

- 1/25,000-200,000 births
- Autosomal dominant disorder
  - STK11/LKB11 on Chr 19: possible tumor suppressor gene
  - 75-94% of PJS patients
- Benign hamartomatous polyp in GI tract
- Hyperpigmented macules on lips and oral mucosa

- **Diagnosis: 2 of the 3**
  - Two or more Hamartomatous polyp
  - Mucocutaneous lesions
  - Family Hx of PJS

## Cancer risk

- Cumulative risk from age 15 to 64

| Site | Rate/100,000 person-years | Cumulative risk from age 15 to 64 |
|---|---|---|
| All cancers | 1304.6 | 93% |
| Esophagus | 19.8 | 0.5% |
| Stomach | 197.7 | 29% |
| Small intestine | 118.6 | 13% |
| Colon | 296.5 | 39% |
| Pancreas | 118.6 | 36% |
| Lung | 98.8 | 15% |
| Testes | 39.2 | 9% |
| Breast | 438.8 | 54% |
| Uterus | 79.8 | 9% |
| Ovary | 159.6 | 21% |
| Cervix | 119.7 | 10% |

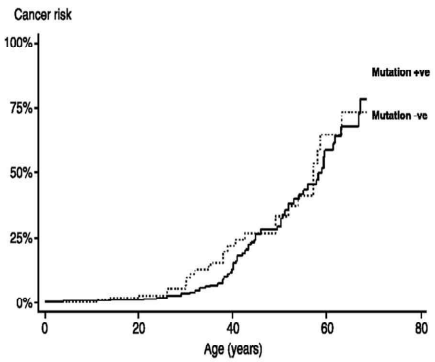


*GASTROENTEROLOGY 2000;119:1447–1453*

*Clin Cancer Res. 2006 May 15;12(10):3209-15*

## Cancer risk

• Relative cancer risk

| Cancer | RR (CI) | p value[a] |
|---|---|---|
| Total ($n$=52) | 63.858 (47.514–85.823) | <0.001 |
| Gastrointestinal | | |
| Colorectum | 237.918 (154.417–366.572) | <0.001 |
| Small intestine | 2600.601 (1260.315–5366.217) | <0.001[b] |
| Stomach | 50.194 (22.387–112.538) | <0.001 |
| Pancreas | 41.001 (5.759–291.923) | 0.024 |
| Extragastrointestinal | | |
| Ovarian | 151.538 (56.540–406.149) | <0.001 |
| Breast | 28.226 (7.030–113.329) | 0.002 |
| Cervix | 69.505 (22.303–216.605) | <0.001 |
| Lung | 22.906 (8.547–61.392) | <0.001 |
| Bone | 155.467 (21.835–1106.944) | 0.006 |
| Lymphadenoma | 44.684 (6.276–318.145) | 0.022 |

| Site | RR |
|---|---|
| *Any cancer* | 15.1 (CI 10.5–21.2) |
| Males | 8.6 (CI 4.2–15.7) |
| Females | 22.0 (CI 14.1–32.7) |
| Breast | 12.5 (CI 5.1–26.0) |
| Cervix | 55.6 (CI 17.7–134.0) |
| Gynaecological cancers | 27.7 (CI 11.3–57.6) |
| Colorectal | 13.5 (CI 4.3–32.5) |
| Males | 11.2 (CI 1.9–37.0) |
| Females | 17.0 (CI 2.8–56.0) |
| *Pancreas* | 139.7 (CI 61.1–276.4) |
| Males | 88.6 (CI 22.6–241.6) |
| Females | 245.4 (CI 78.0–591.9) |
| *Gastrointestinal cancers* | 126.2 (CI 73.3–203.4) |
| Males | 90.4 (CI 39.6–178.9) |
| Females | 192.8 (CI 89.5–366.1) |

*Tumour Biol. 2017 Jun;39(6)*

*Dig. Liver Dis. 2013 Jul;45(7):606-11*

## Risk & Surveilance

| Site | % Lifetime Risk | Screening Procedure and Interval | Initiation Age (y) |
|---|---|---|---|
| Breast | 45%–50% | • Mammogram and breast MRI annually[c]<br>• Clinical breast exam every 6 mo | ~ 25 y |
| Colon | 39% | • Colonoscopy every 2–3 y | ~ Late teens |
| Stomach | 29% | • Upper endoscopy every 2–3 y | ~ Late teens |
| Small intestine | 13% | • Small bowel visualization (CT or MRI enterography or video capsule endoscopy baseline at 8–10 y with follow-up interval based on findings but at least by age 18, then every 2–3 y, though this may be individualized, or with symptoms) | ~ 8–10 y |
| Pancreas | 11%–36% | • Magnetic resonance cholangiopancreatography with contrast or endoscopic ultrasound every 1–2 years | ~ 30–35 y |
| Ovary[c] (typically benign sex cord/Sertoli cell tumors)<br>Cervix (typically cervical adenoma malignum)<br>Uterus | 18%–21%<br>10%<br>9% | • Pelvic examination and Pap smear annually<br>• Consider transvaginal ultrasound | ~ 18–20 y |
| Testes (typically sex cord/Sertoli cell tumors) | | • Annual testicular exam and observation for feminizing changes | ~ 10 y |
| Lung | 15%–17% | • Provide education about symptoms and smoking cessation<br>• No other specific recommendations have been made | |

*NCCN guideline*

## Risk & Surveilance

- **Annually check**
  - Mammography and MR breast
  - Pap smear & pelvic exam
  - Testicular exam
  - MRCP or EUS (1-2 years)

- **Biannually check**
  - EGD, colono (2-3 years)
  - CT or MR enterography or capsule scdoscopy (2-3 years)

memo

MEMO