

CASE PRESENTATION

충남대학교병원 | 이현석
이엄석

60 / M 정O관 (내원일 : 2021.08.17)

- Chief complaint

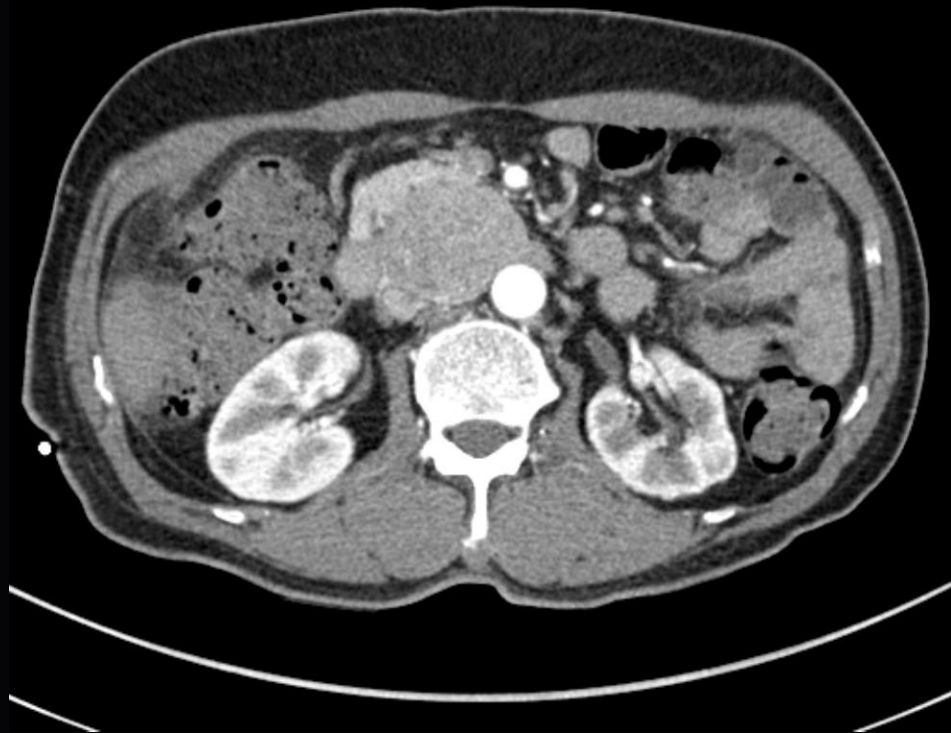“Retropancreatic mass”

Onset)

Present illness

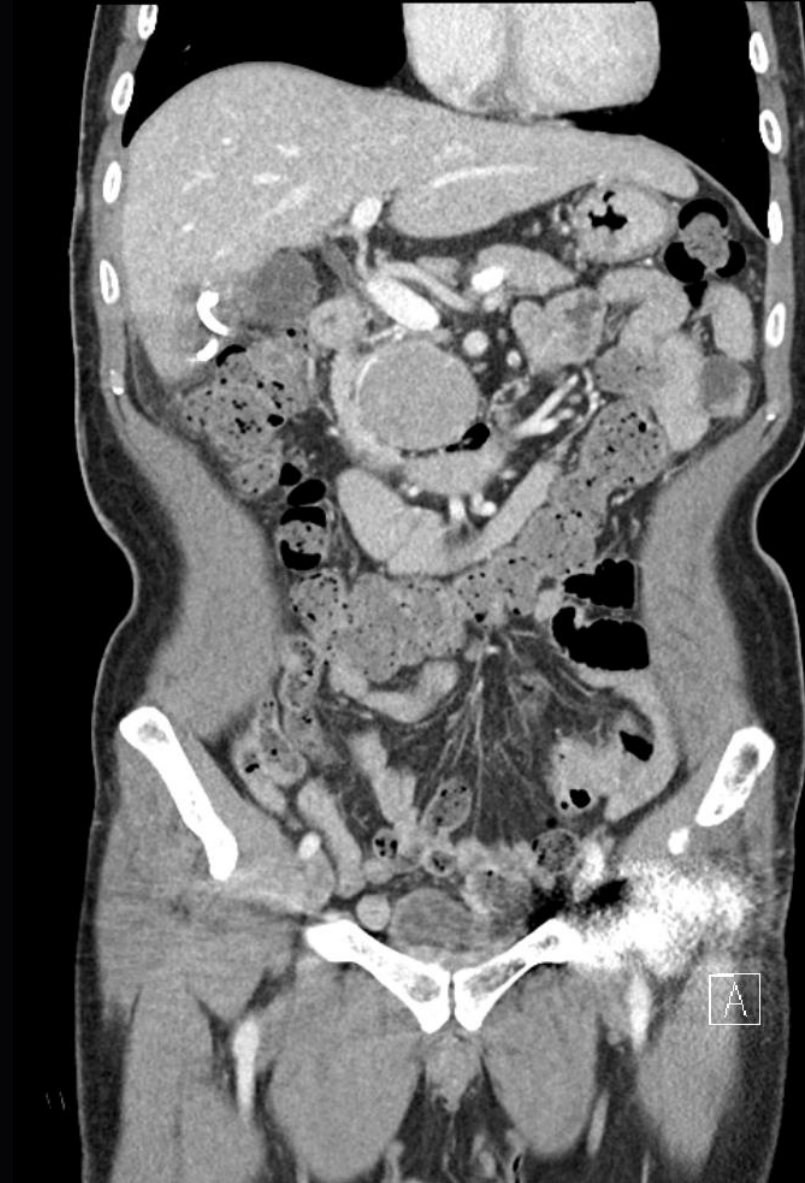- 2021.06.02) 내원 보름 전 부터 지속되는 발열을 주소로 응급실 내원
Liver abscess로 입원하여 PCD insertion 및 항생제 치료
당시 촬영한 APCT 상 5cm soft tissue in aortocaval space 확인됨
- 2021.08.17) EUS-FNB 위해 입원함

APCT (21.06.29)



DDx :

1. Possible lymphoma
2. Possible GIST or neuroendocrine tumor



Past medical history

- **DM/HT/TB/Hepatitis (+/+/-/-)**
- **Medication history (+)**
Nebivolol, Valsartan
Insulin, Linagliptin, Metformin
Atorvastatin
- Operation history (-)

Social history / Family history

- 소주 : 5병/일, 30여년

Problem list

#1. Retropancreatic mass

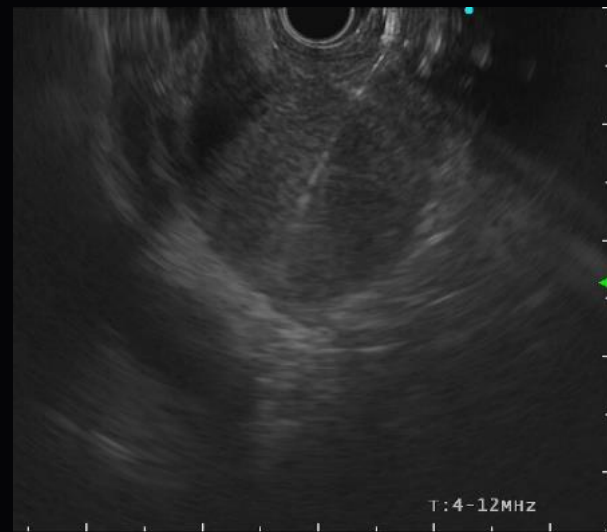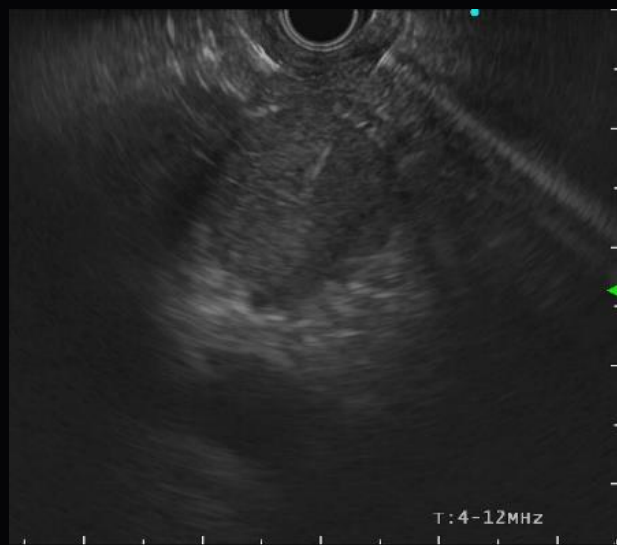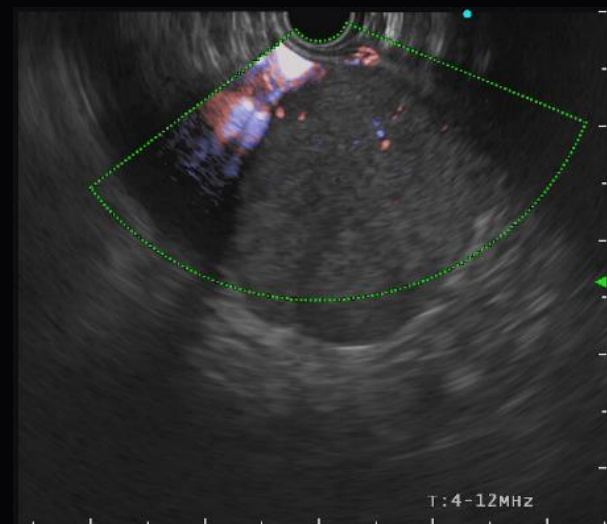
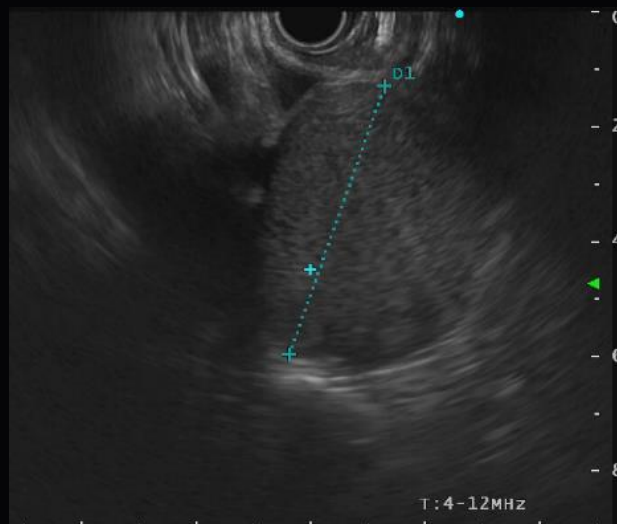Assessment / Plan

#1.

A) Retropancreatic mass

P) EUS-FNB

EUS - FNB (21.08.18)



HD#2 (21.08.18)

EUS-FNB
시작

EUS-FNB
종료

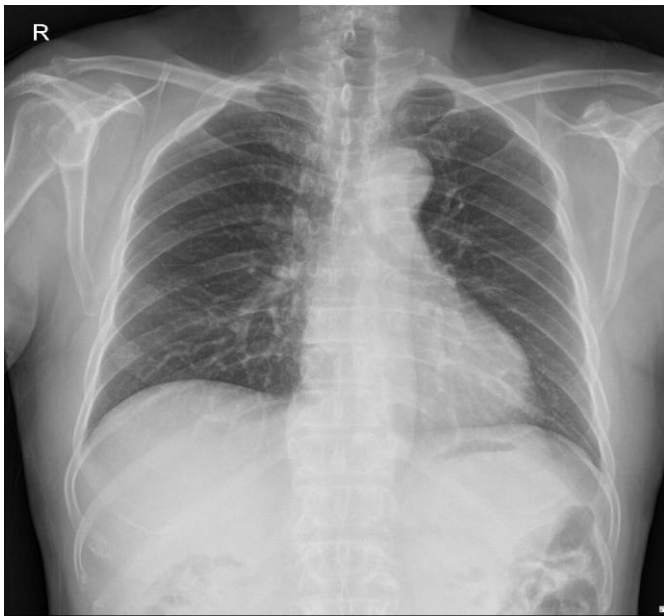
병동 인계 후

dyspnea, nausea,
profuse sweating

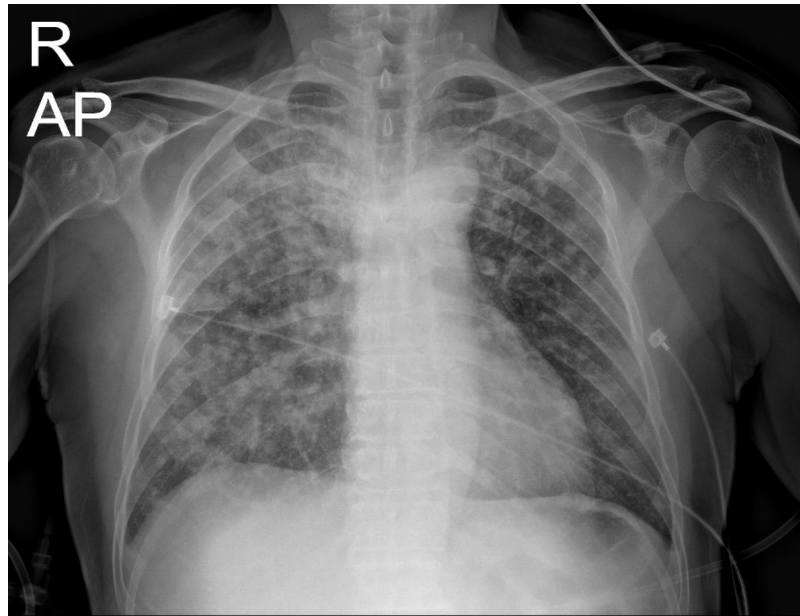
	6A	2P	2P30	2P40	2P45	3P47
SBP	129	130	134	154	180	189
DBP	78	68	81	85	78	132
PR	63	56	70	89	65	102
RR	18	20	18	18	20	24
BT	36.9	36.8			36.8	36.9

HD #2 (2021.8.18)

ABGA 7.20-46-62-18



EUS – FNB (before)



EUS – FNB (1 hr later)

→ intubation 시행 (endotracheal tube suction 시 다량의 mucus secretion)

Impression

ARDS (due to aspiration pneumonia vs pulmonary edema)
s/p)EUS-FNB

Assessment / Plan

ICU transfer & mechanical ventilator support

항목	동기	6	15:47	16:05	16:24	16:57	17:00	17:20	18:00	19:00	20:00	21:00	21:30	22:00	22:20	22:30	23:00	00:00	00:30	01:00	02:00	02:30
v 활력징후																						
SBP (mmHg)		189	182					161	108	108	109	79	93	57		65	95	91		70	82	77
DBP (mmHg)		132	17					116	84	77	83	53	71	43		49	72	66		54	58	55
MBP (mmHg)								127	89	84	88	59	76	47		52	77	72		57	63	59
PR (회/min)		102	97					111	122	101	94	90		89			90	90	115	92	93	
RR (회/min)		24						15	18	22	22	14		22			22	22	35	22	22	
BT (°C)		36.9						37.2	37.6	37.7	37.7	38.0		38.0			38.3	38.6		38.5	38.5	
SpO2 (%)		70						86	95	95	98	97		99			95	97		95	95	86
의식반응								P										P				
EWS		6						8	4	5	4	3		5			6	8		8	8	
EKG								NSR										NSR				
ISBP (mmHg)									117	107	112	93		59			90	82		64	73	
IDBP (mmHg)									76	73	76	64		44			65	61		50	57	
IMBP (mmHg)									88	84	87	74		50			73	69		55	63	

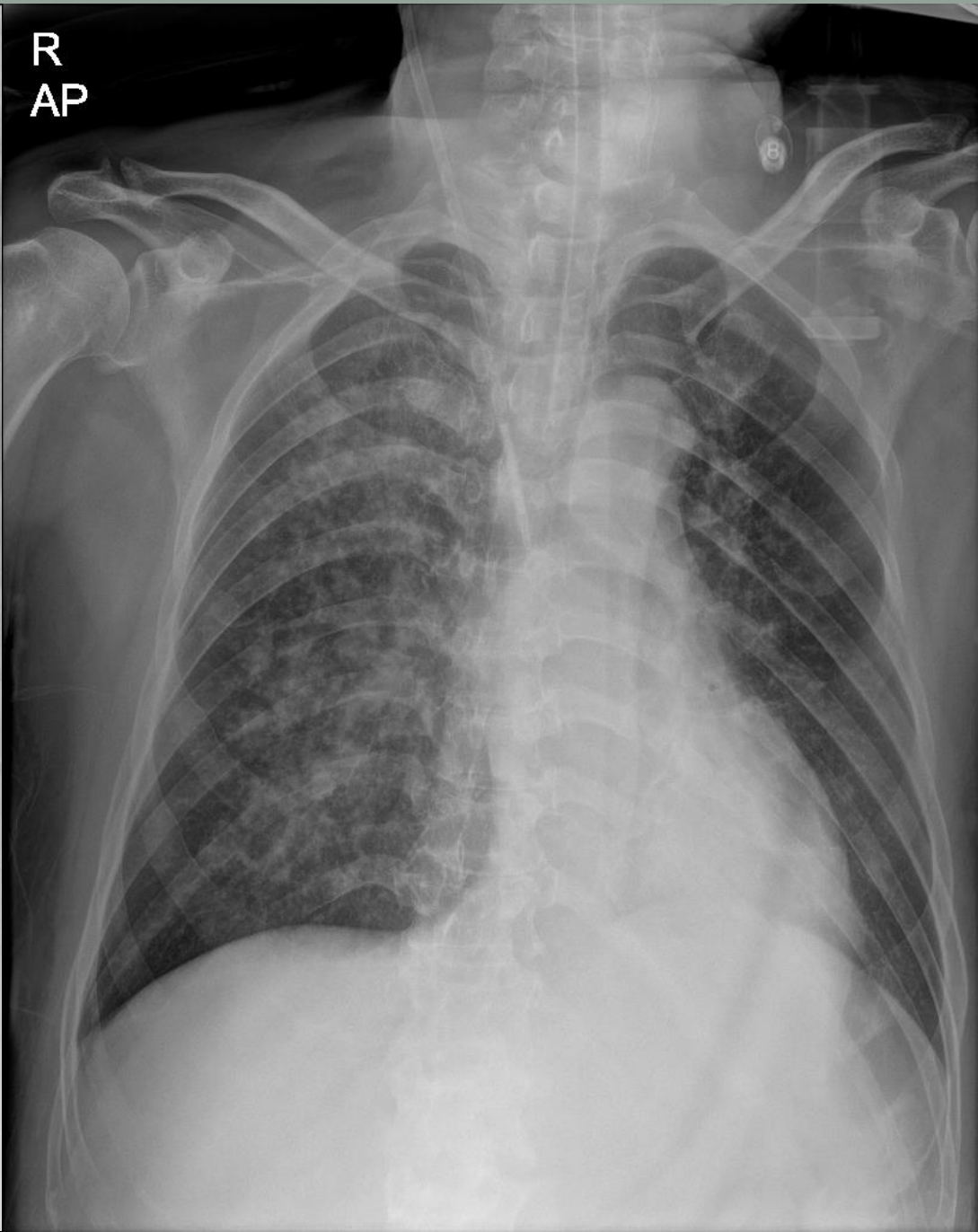
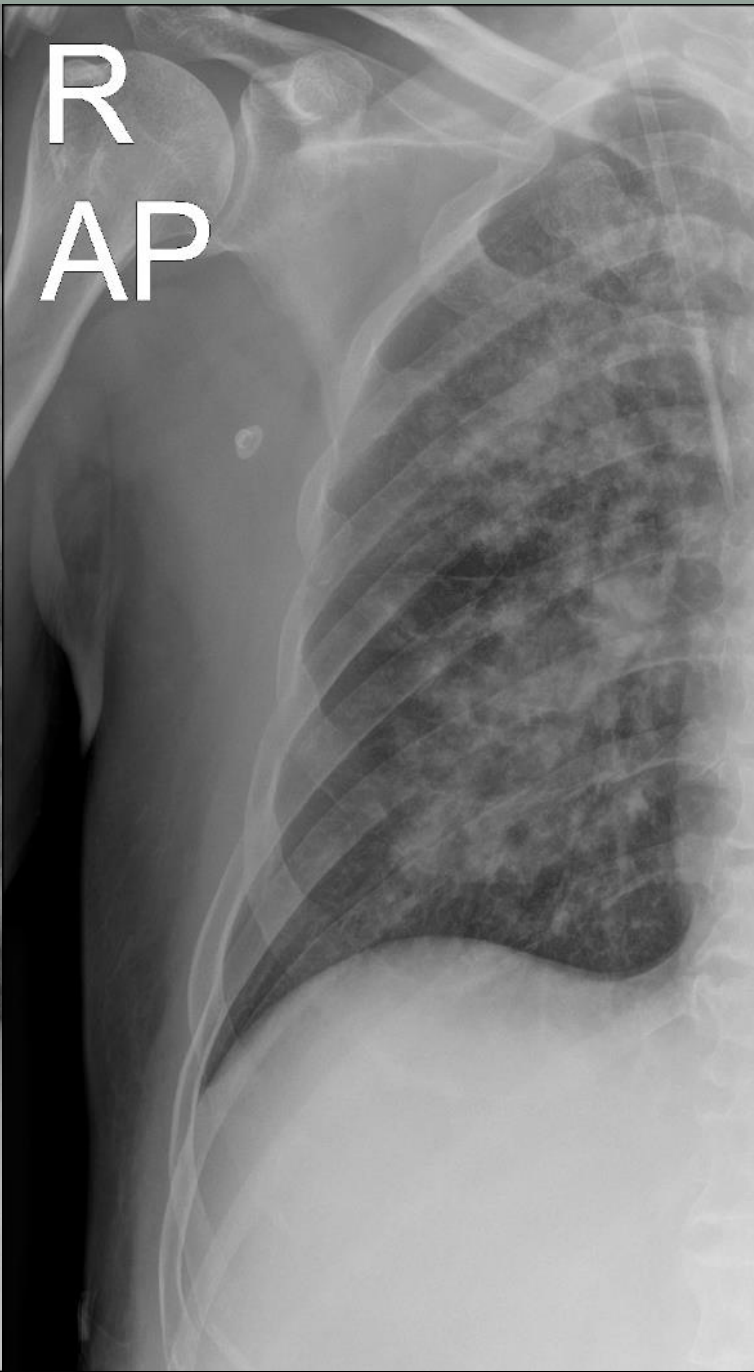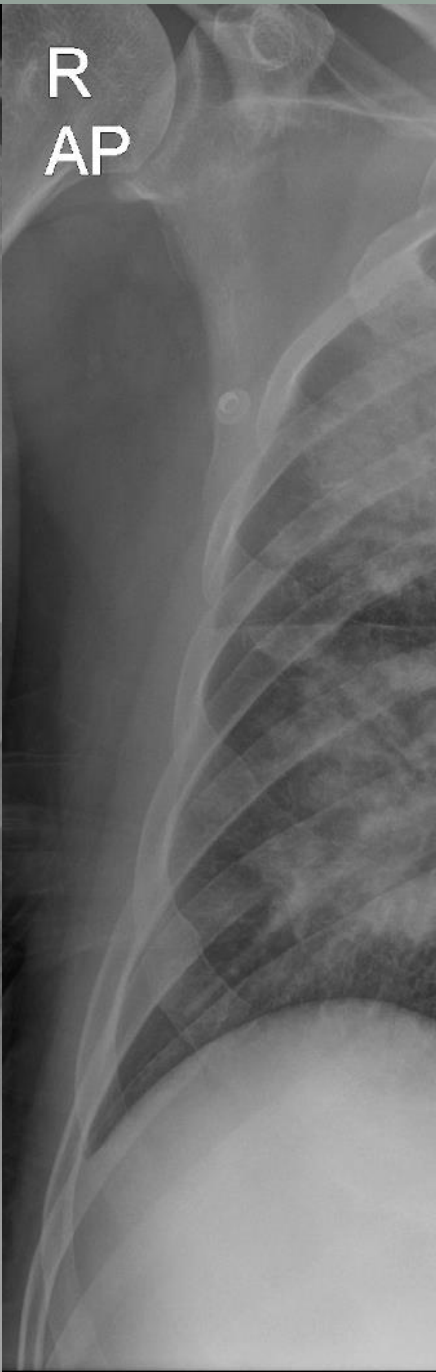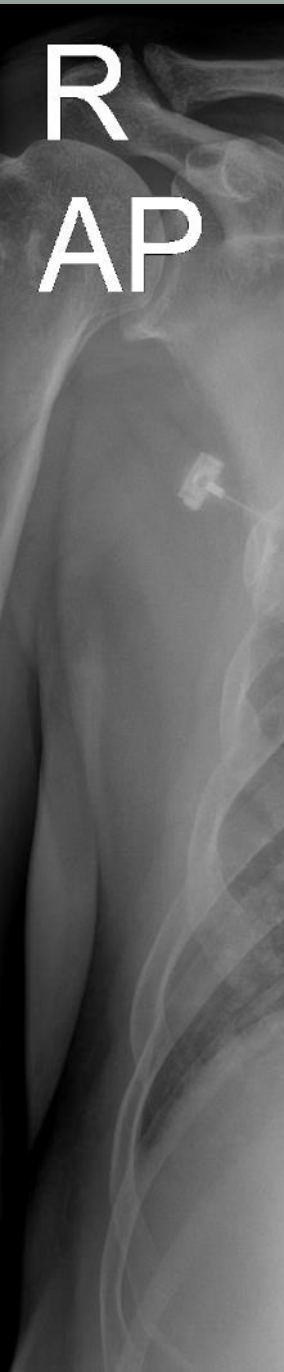항목	14:00	14:20	14:30	15:00	16:00	17:00	18:00	19:00	20:00	21:00	21:30	22:00	23:00	00:00	01:00	02:00	03:00	04:00	05:00	06:00	
입원																					
▼ 전동/외출/부재																					
전동/외출/부재																					
▼ 활력징후																					
SBP (mmHg)	139	129		110	101	134	110	125	145	181	181	156	137	105	80	82	87	112	85	92	
DBP (mmHg)	94	75		73	65	92	70	79	92	130	130	114	99	77	63	63	64	83	69	68	
MBP (mmHg)	104	91		80	73	102	78	89	104	140	140	122	107	83	66	67	69	89	72	73	
PR (회/min)	105		122	111	110	100	112	97	96	137		134	125	109	121	103	108	109	107	105	
RR (회/min)	22			22	22	22	22	22	22	22		22	22	22	22	22	22	22	22	22	
BT (°C)	36.7			37.3	37.2	37.3	37.2	37.4	37.2	37.2		37.1	36.4	36.2	36.2	36.3	36.3	36.2	36.3	36.2	
SpO2 (%)	91		93	100	100	100	100	100	100	94		97	99	99	100	97	100	100	100	100	

07:00	08:00	09:00	10:00	11:00	12:00	12:30	13:00	13:30	14:00	15:00	16:00	16:20	17:00	18:00	19:00	20:00	21:00	22:00	23:00	

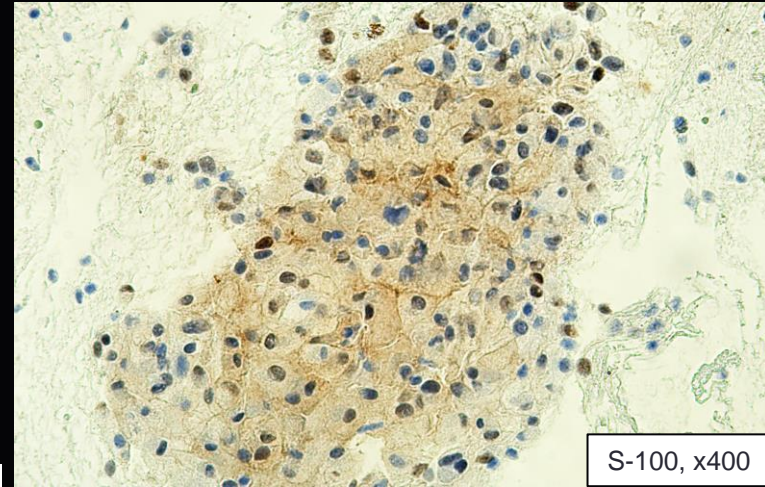
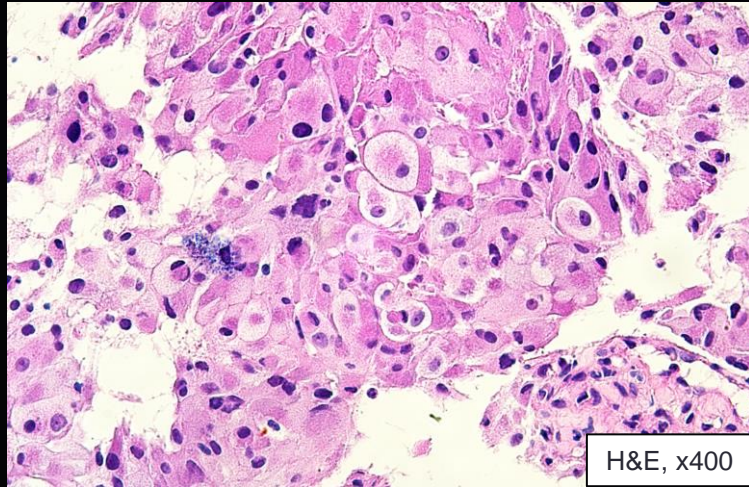
132	99	98	86	97	124		160	171	165	113	89	89	91	93	120	103	128	133	132
92	70	73	62	66	83		108	110	108	81	52	52	65	67	80	78	86	91	90
102	76	78	67	71	91		121		121	87	60	60	69	72	89	83	95	100	100
105	104	110	102	121	110		115	150	168	152	159	162	120	116	95	97	102	99	99
22	22	22	22	22	22		20		20	20	22		22	22	22	22	22	22	22
36.6	36.6	36.7	36.4	36.4	36.6		36.5		36.9	37.8	38.0		37.9	37.8	37.1	36.9	37.8	37.5	37.3
100	100	100	100	100	100	100	94		94	99	99		100	100	100	100	100	99	100

ICU

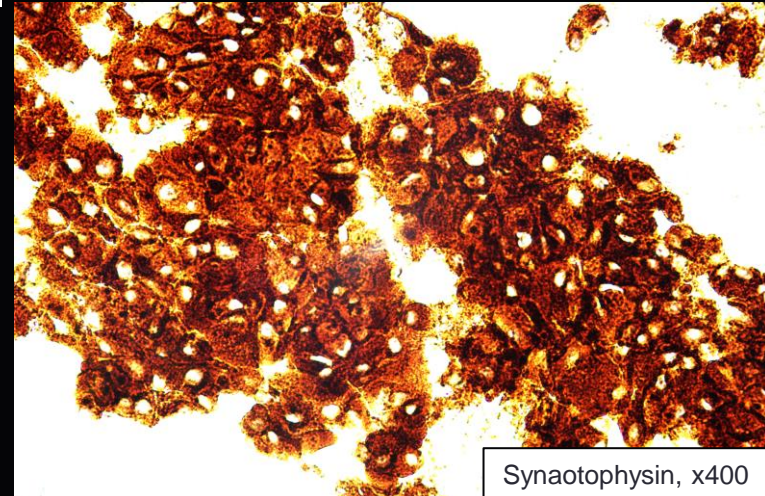
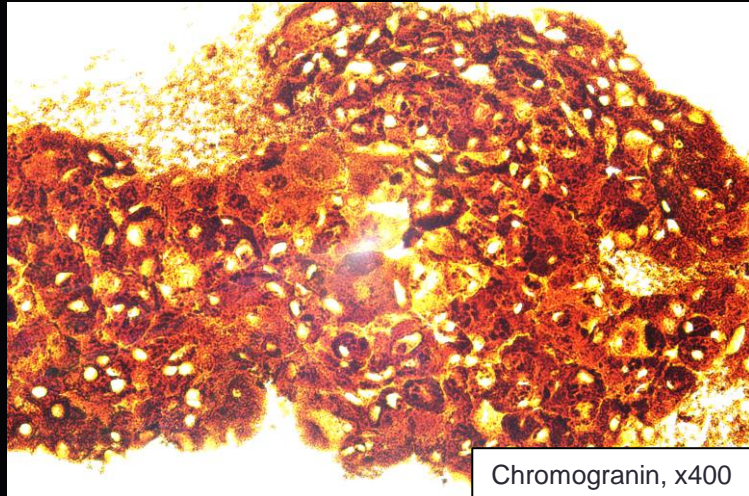
HD#2	HD#3	HD#4	HD#5	HD#6	HD#7
Intubation					
Norepinephrine					
Vasopressin					
Dobutamine					
	CRRT				
	Nicardipine				
	Esmolol				



Biopsy (2021.08.18)



Paraganglioma



impression

- # Retroperitoneal paraganglioma(extra-adrenal pheochromocytoma)
- # Neurogenic pulmonary edema due to catecholamine crisis s/p) EUS-FNB

Assessment / Plan

Plasma & 24hr urine – metanephrine, normetanephrine

PET-CT

Phenoxybenzamine (non selective alpha blocker) & surgical resection

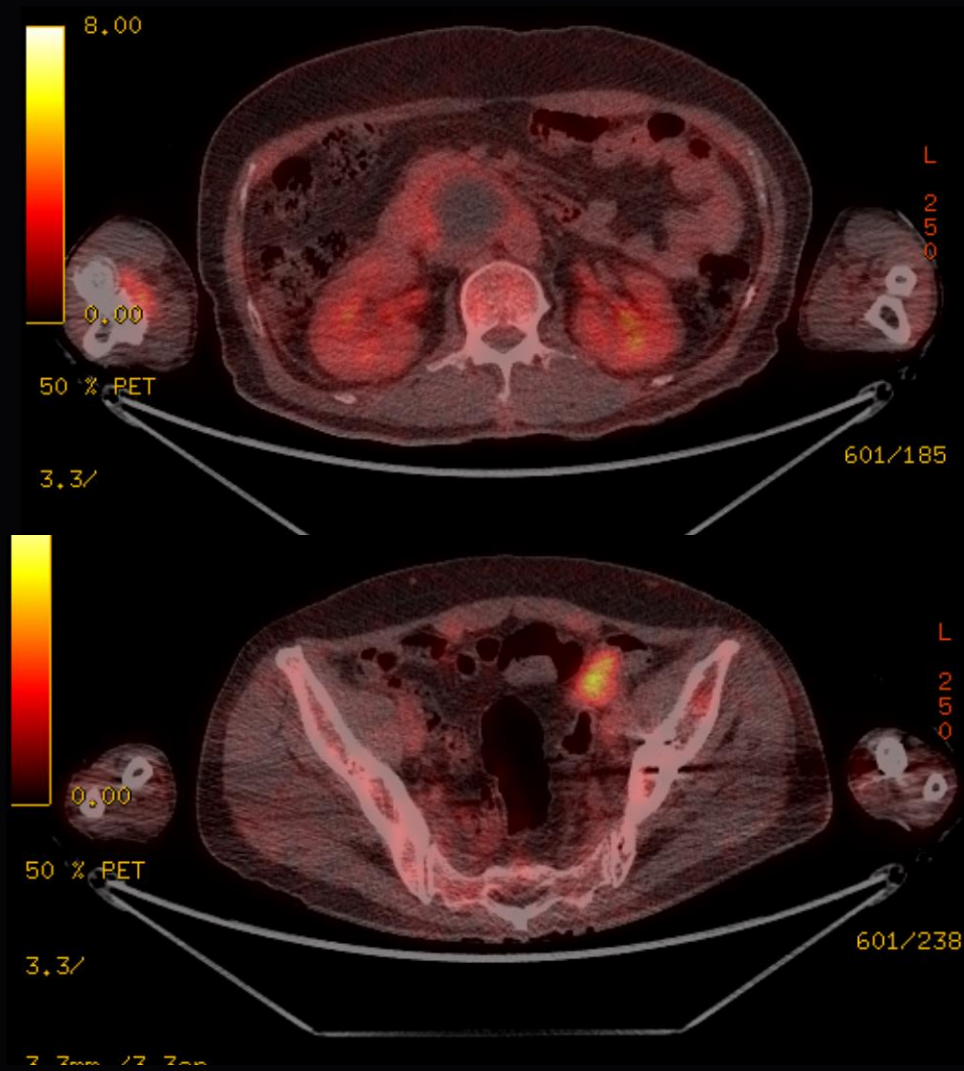
Lab. (21.08.24)

Plasma			Urine		
Metanephrine	> 20.21	0~0.49 nmol/L	Metanephrine	> 1814.7	52~341ug/day
Normetanephrine	> 45.33	0~0.89 nmol/L	Normetanephrine	> 3814.3	88~444ug/day
			Epinephrine	83.3	0.0~20.0ug/day
			Norepinephrine	398.0	15.0~80.0ug/day
			VMA(정량)	22.0	0~8mg/day

ICU

HD#2	HD#3	HD#4	HD#5	HD#6	HD#7	HD#8	HD#9	HD#10	HD#11	HD#12	HD#13	HD#14	HD#15
Intu.													Extu.
Norepinephrine						Norepinephrine							
Vasopressin													
Dobutamine													
CRRT													
Nicardipine													
Esmolol													
							Terazosin 1mg, qd		Terazosin 2mg, bid				

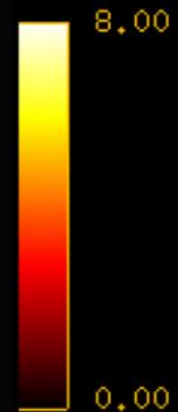
PET (21.09.08)



Coronal Volume 2/Volume 1
Ex: 38700

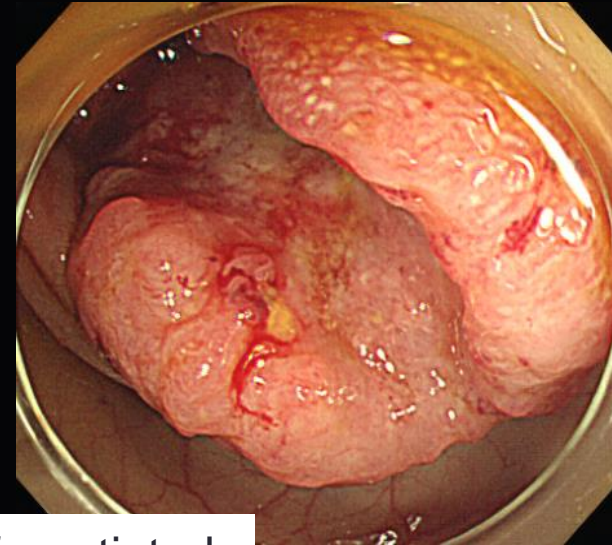
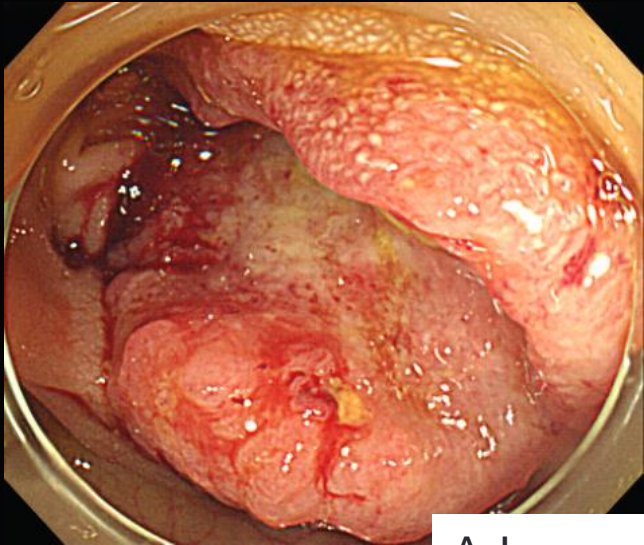
Se: 6
A: 2.3

DFOV 196.6 cm

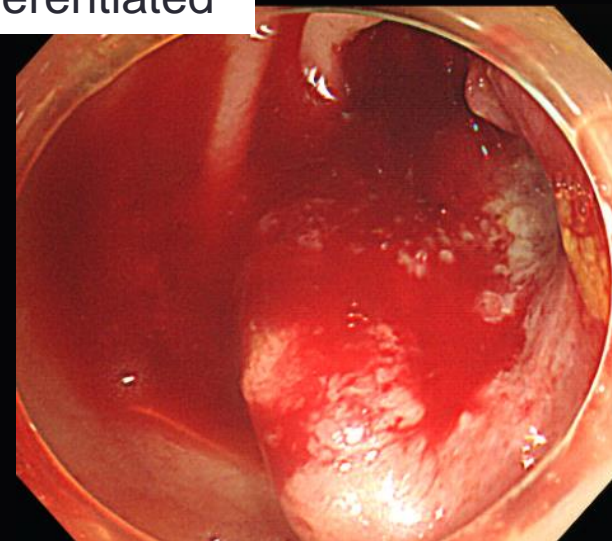
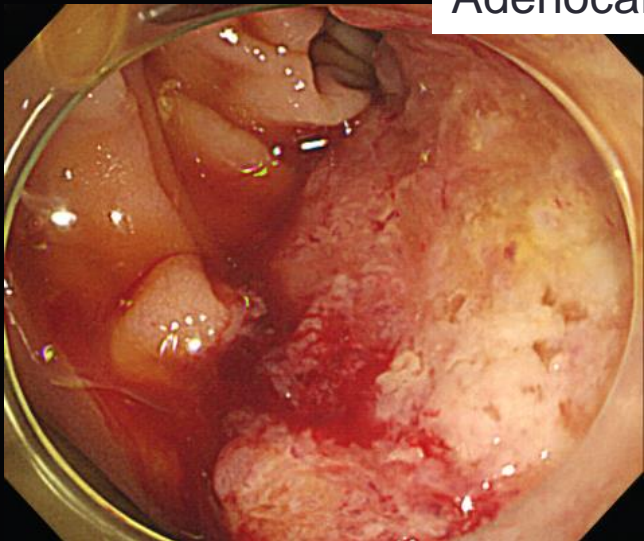


DDx. Additional paraganglioma mass in proximal sigmoid colon vs. Sigmoid colon cancer

Colonoscopy (21.09.14)



Adenocarcinoma, moderately differentiated



Operation (21.12.09)

- ◎ 병 리 진 단

1. Colon including terminal ileum, anterior resection:

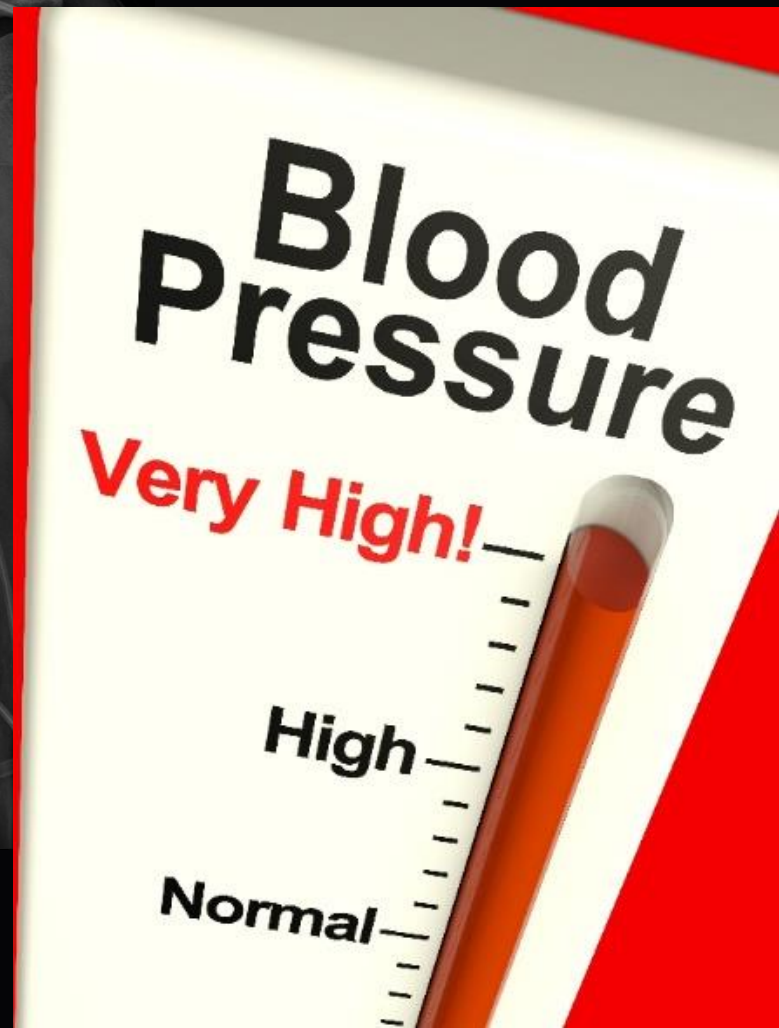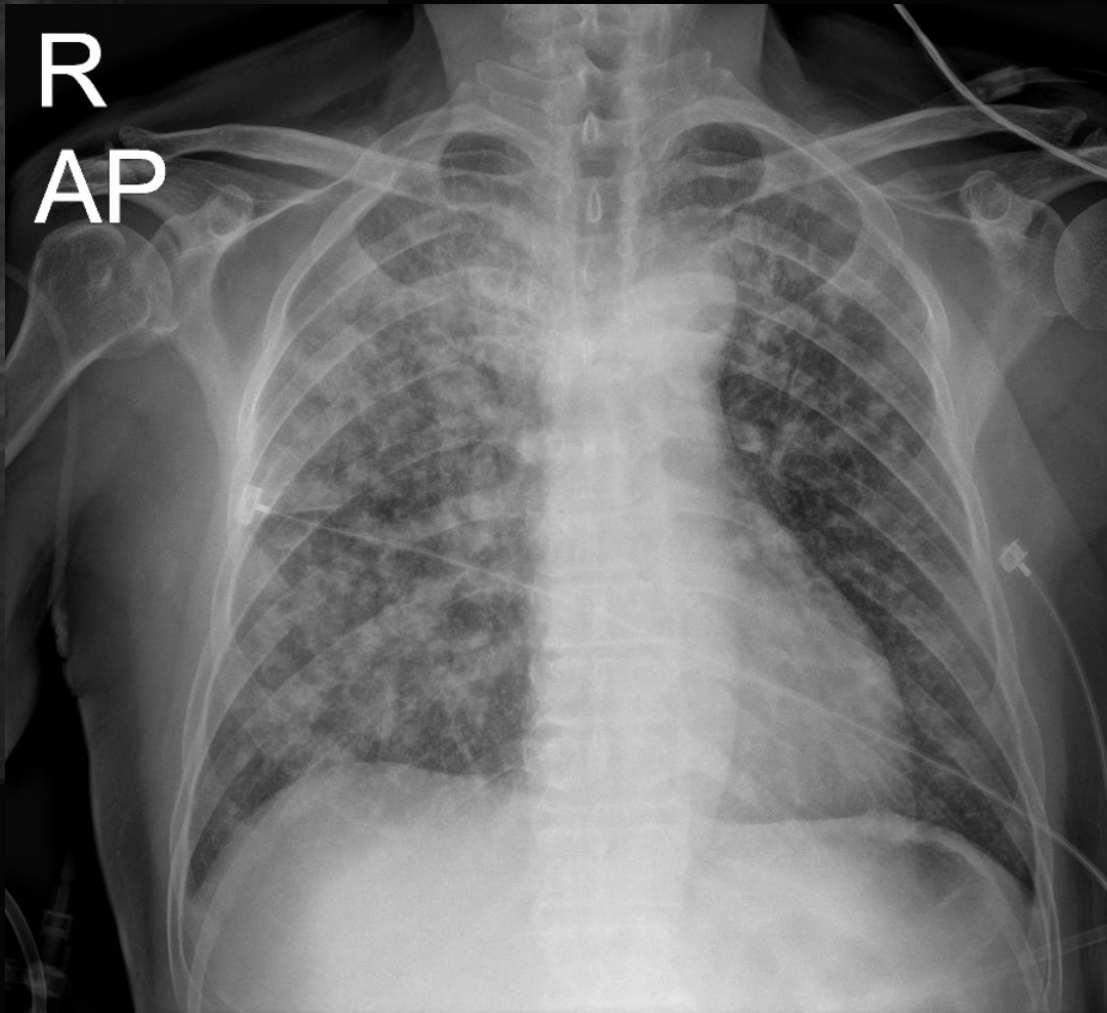
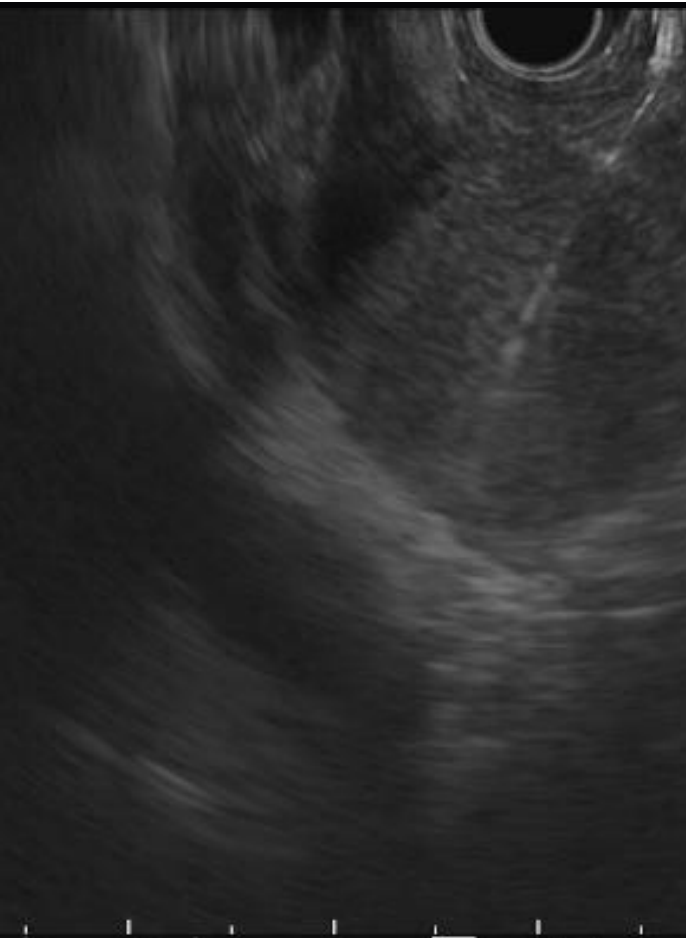
- **ADENOCARCINOMA**, MODERATELY DIFFERENTIATED, 3.6 X 2.7 X 0.6 CM (A1-A4)

2. Soft tissue, "aortocaval mass", excision:

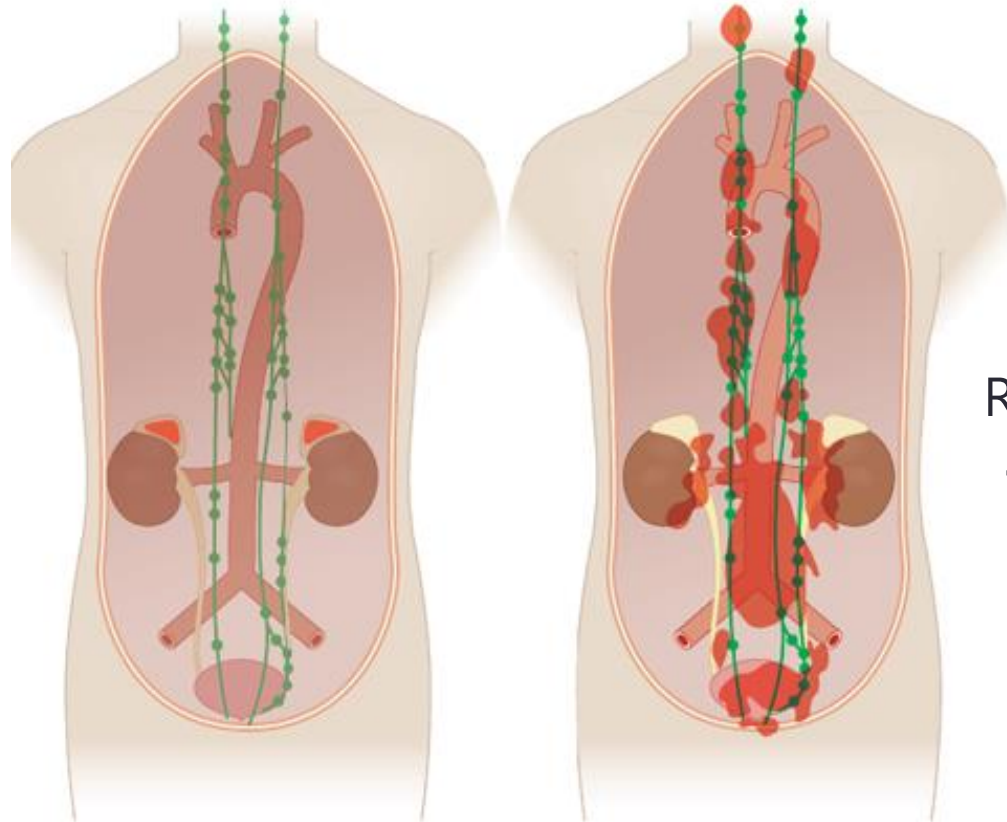
- **Paraganglioma** (D1,D2)

- 1) tumor size: 1.9 x 1.6 x 1.5 cm

- 2) necrosis: present (>50%)



Discussion



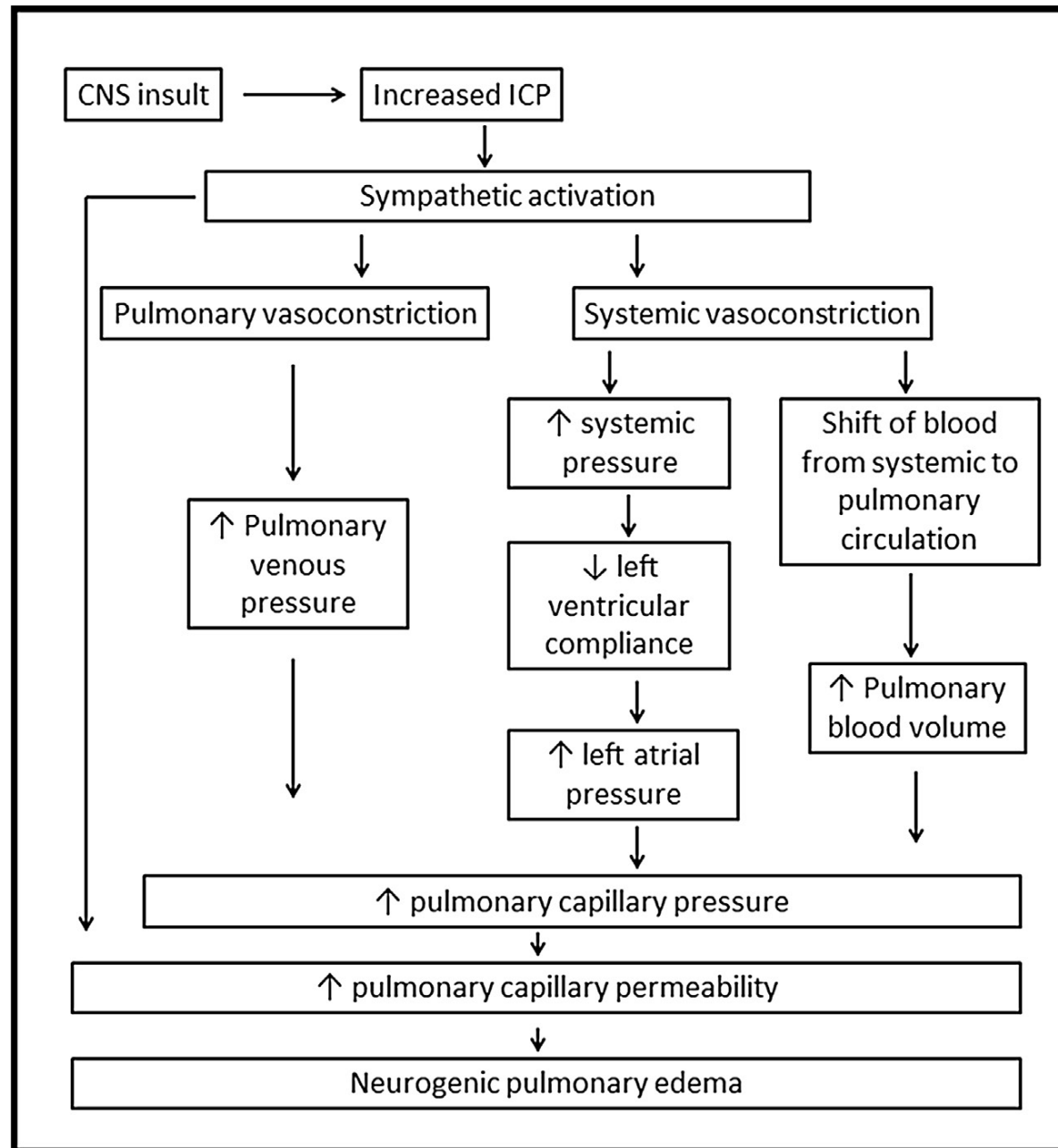
A Adrenal
pheochromocytoma

B Extra-adrenal
pheochromocytoma

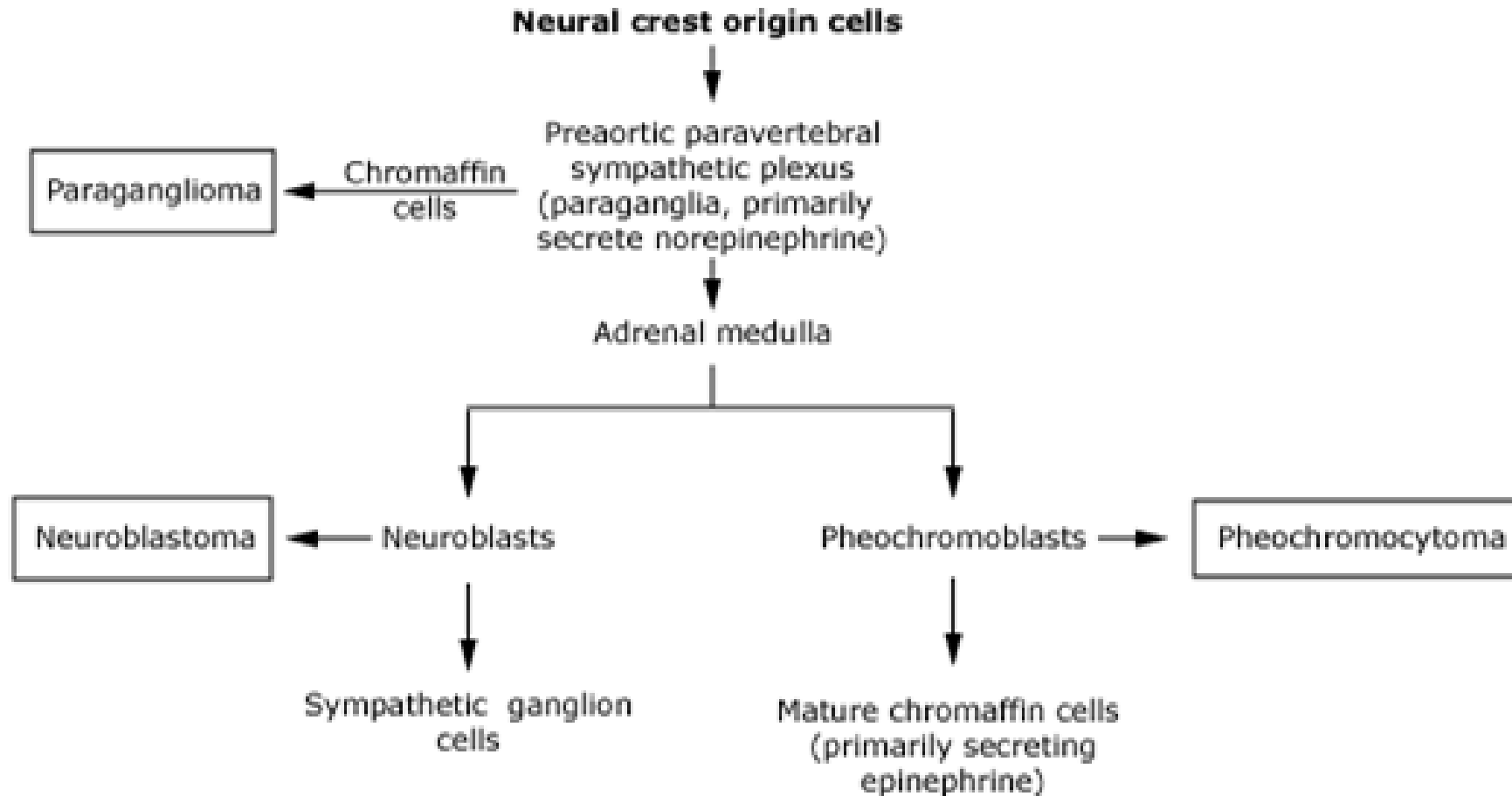
Source: Joseph Loscalzo, Anthony Fauci, Dennis Kasper, Stephen Hauser, Dan Longo, J. Larry Jameson: Harrison's Principles of Internal Medicine, 21e
Copyright © McGraw Hill. All rights reserved.

Retroperitoneal & paraduodenal mass

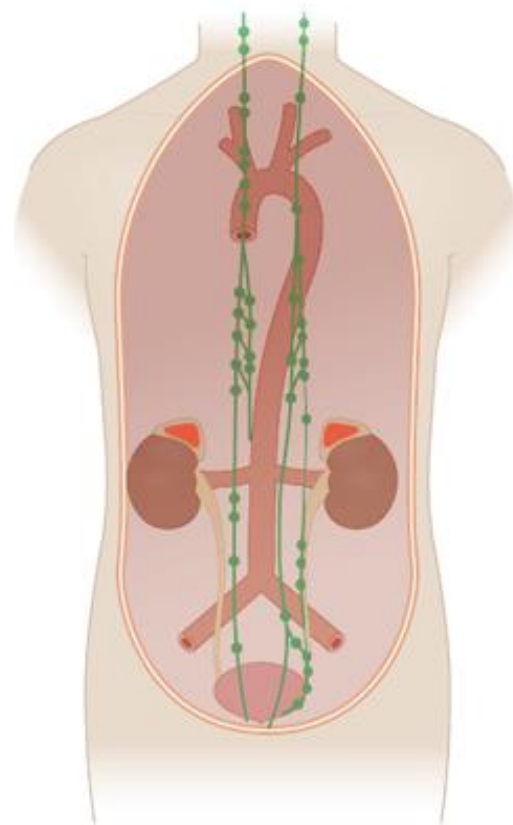
→ EUS 시행 전 routine screening for pheochromocytoma?



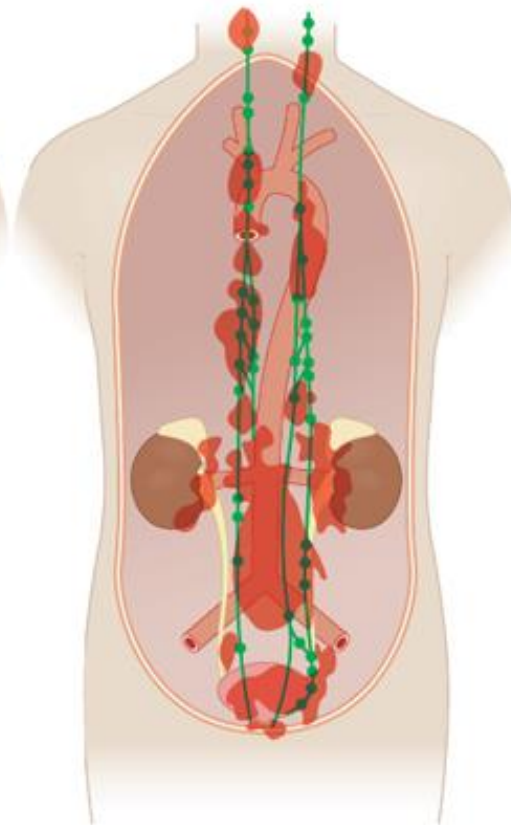
Paraganglioma



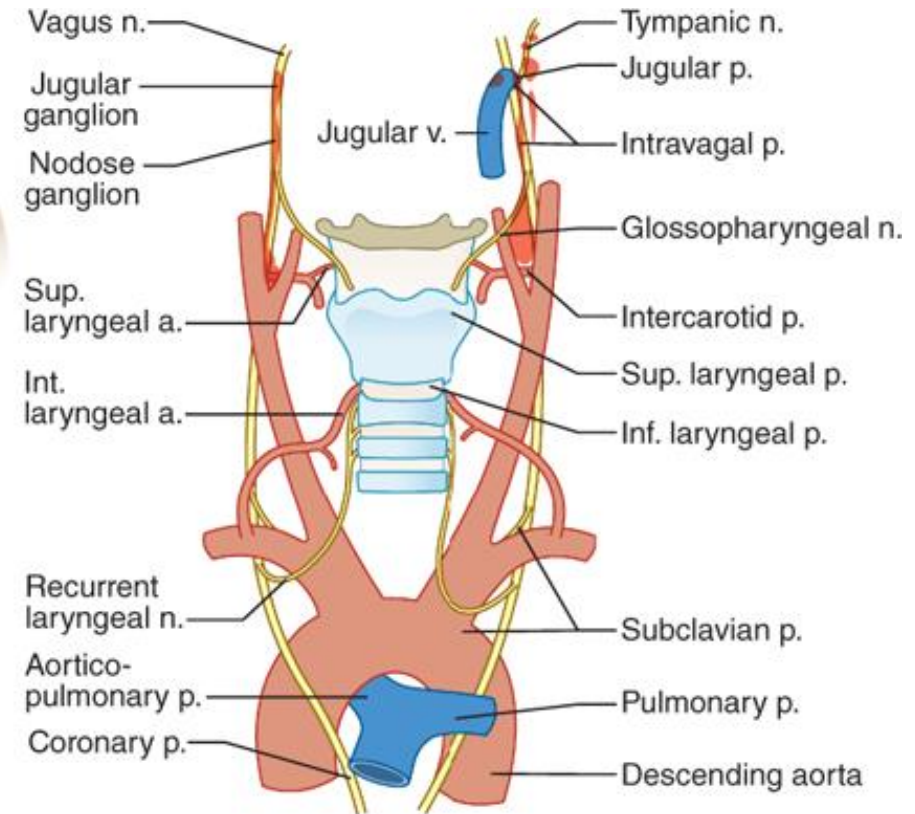
Paraganglioma



A Adrenal pheochromocytoma



B Extra-adrenal pheochromocytoma



C Head and neck paraganglioma

Source: Joseph Loscalzo, Anthony Fauci, Dennis Kasper, Stephen Hauser, Dan Longo, J. Larry Jameson: *Harrison's Principles of Internal Medicine*, 21e
Copyright © McGraw Hill. All rights reserved.

