

Session I

Endoscopic Dissection with OTSC Device Case of Early Gastric Cancer Patient

Seung Ah Jeong

Digestive Disease Center, CHA Bundang Medical Center, CHA University, Bundang, Korea

1. Case presentation

Endoscopic dissection with OTSC device case of EGC

2. Diagnosis

Early gastric cancer

3. Therapy and Clinical course

OTSC

4. Conclusion

OTSC

Key words: OTSC

REFERENCES

1. GASTROINTESTINAL ENDOSCOPY Volume 66, No. 1: 2007
2. Richter-Schrag HJ et al. OTSC in high-risk gastrointestinal bleeding
3. Journal of Gastroenterology and Hepatology 34:22-30, 2019

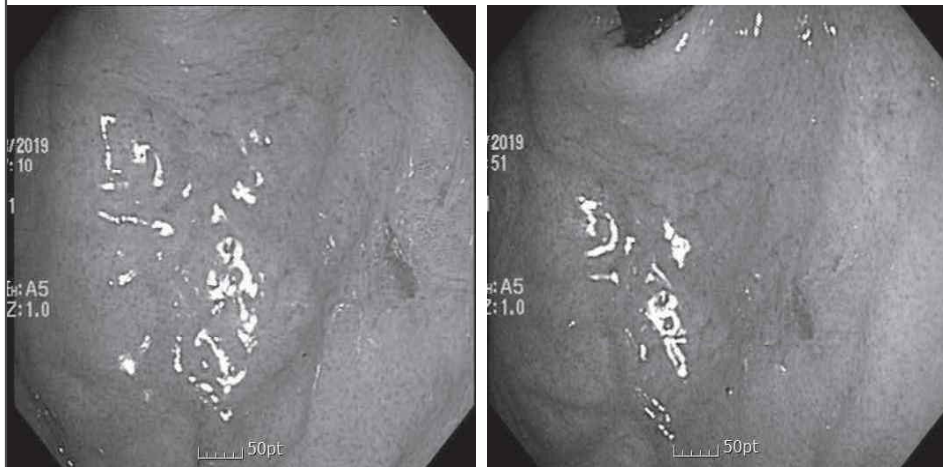41/M

Chief complaints EGC work up

Present illness

기저질환 없는 41세 남자환자 내원 2개월 전 검진으로 시행한 위 내시경 검사 및 조직검사 상 중등도 분화도의 위 선암 소견 보였으나, 타원 추가 조직검사 상 이상 소견 보이지 않아 추가 검사 및 치료 위해 본원 내원

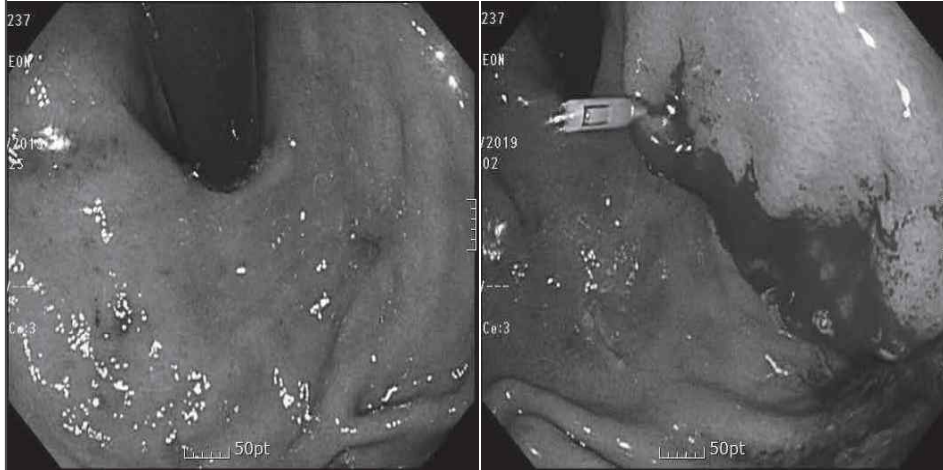
EGD (19.09.03)- 외부 검진(1st Bx.)



Stomach, fundus, anterior wall

: TUBULAR ADENOCA. Moderately differentiated

EGD c hemoclipping (19.09.17)- 외부 병원(2nd Bx.)



▪ 외부 병원(2nd Bx.)

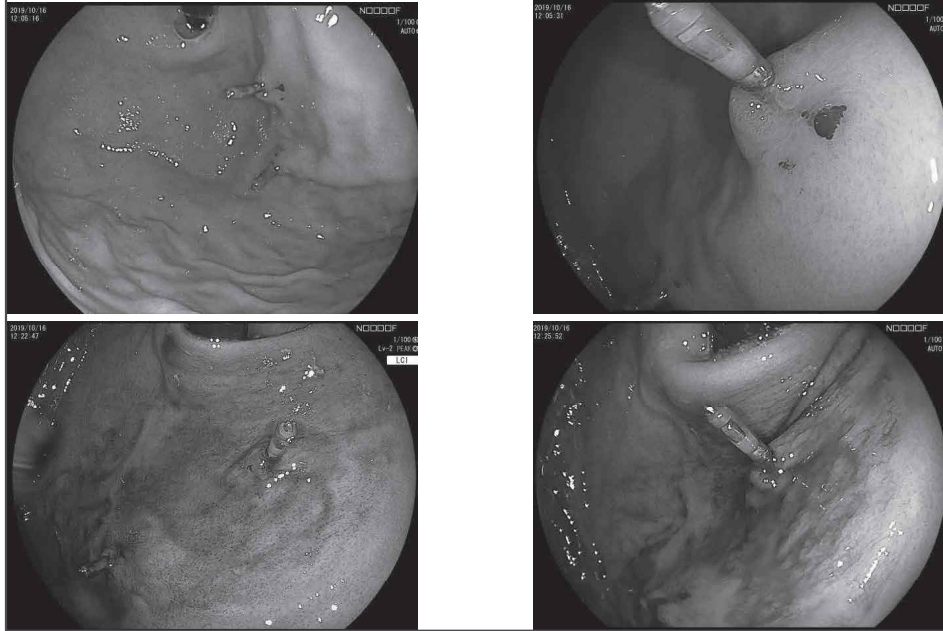
Stomach, fundus, anterior wall

: Chronic gastritis with lymphoid aggregate

Cf. 외부 검진 (1st Bx.) slide review

: TUBULAR ADENOCA. Moderately differentiated

EGD (19.10.15) - 본원



▪ Tumor maker

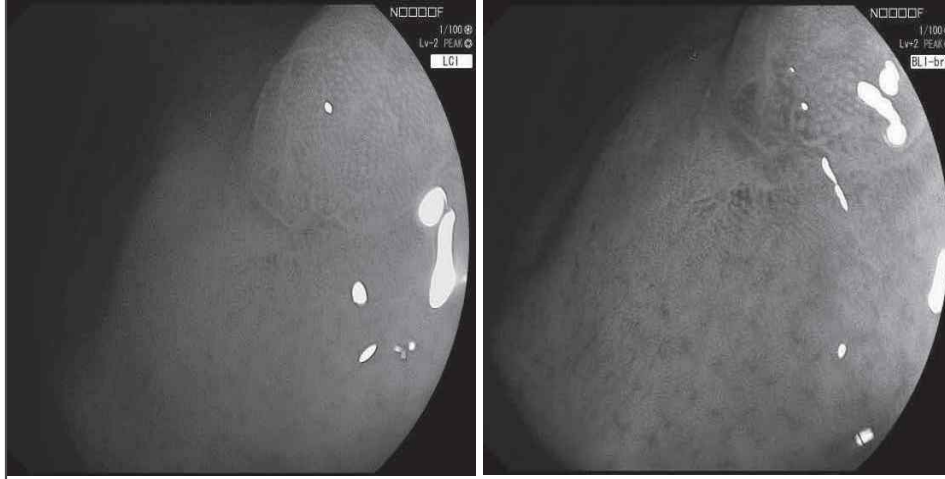AFP	1.8 ng/mL
CEA	1.44 ng/mL
CA19-9	14.68 U/mL

▪ 조직 외부 슬라이드 판독(1st. Bx)

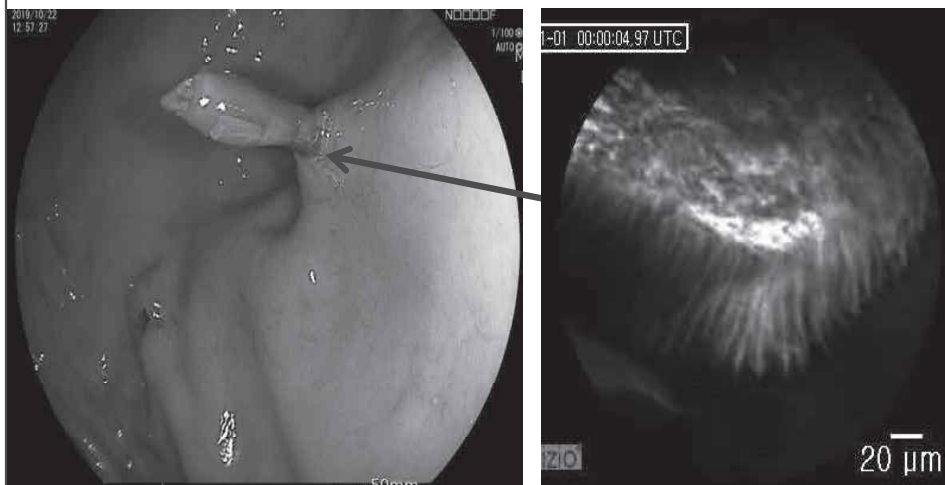
Stomach, fundus, anterior wall, endoscopic biopsy :

ADENOCARCINOMA, moderately differentiated

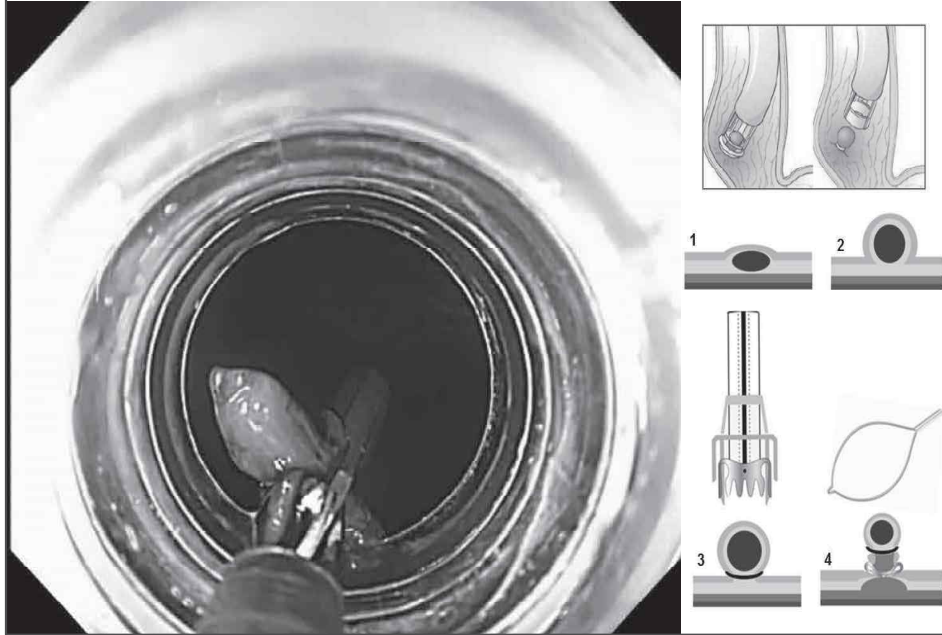
LCI/BLI (19.10.15)



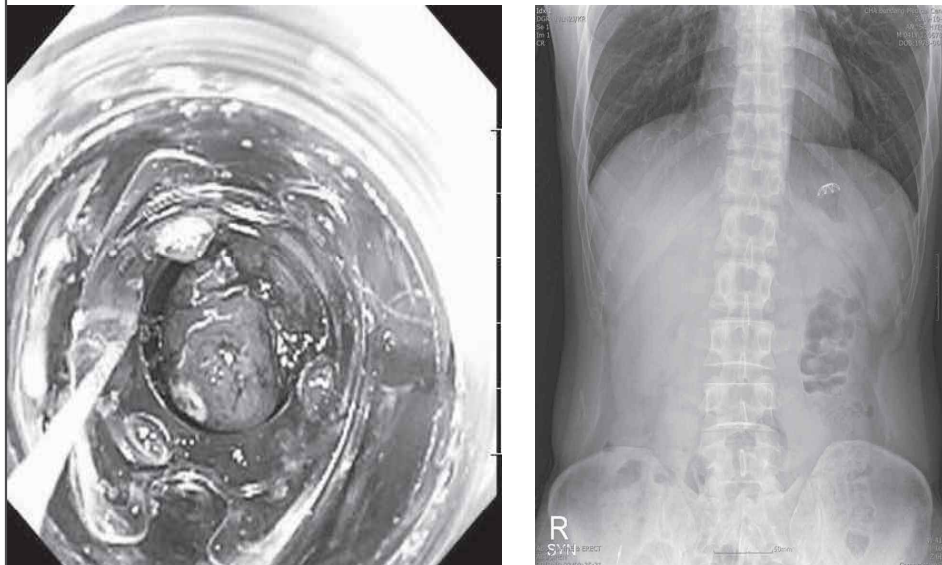CLE (19.10.22)



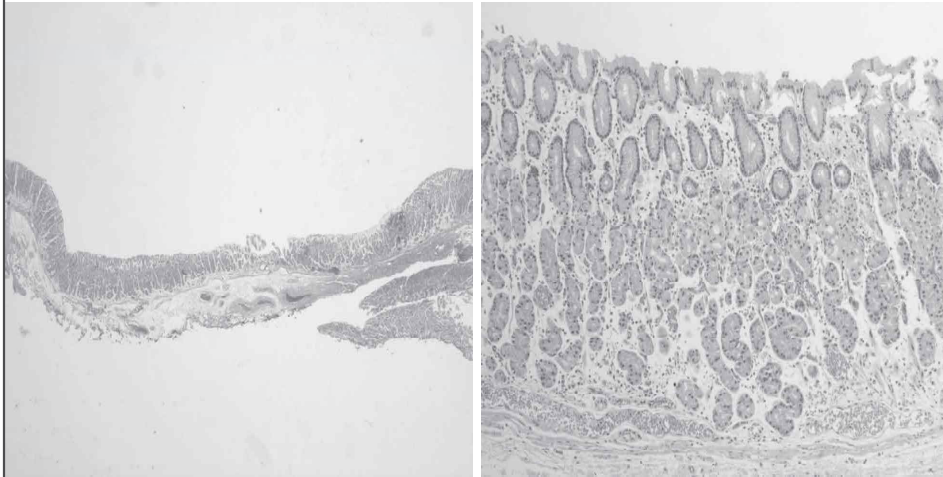
Endoscopic resection with OTSC device (19.10.22)



Endoscopic resection with OTSC device (19.10.22)

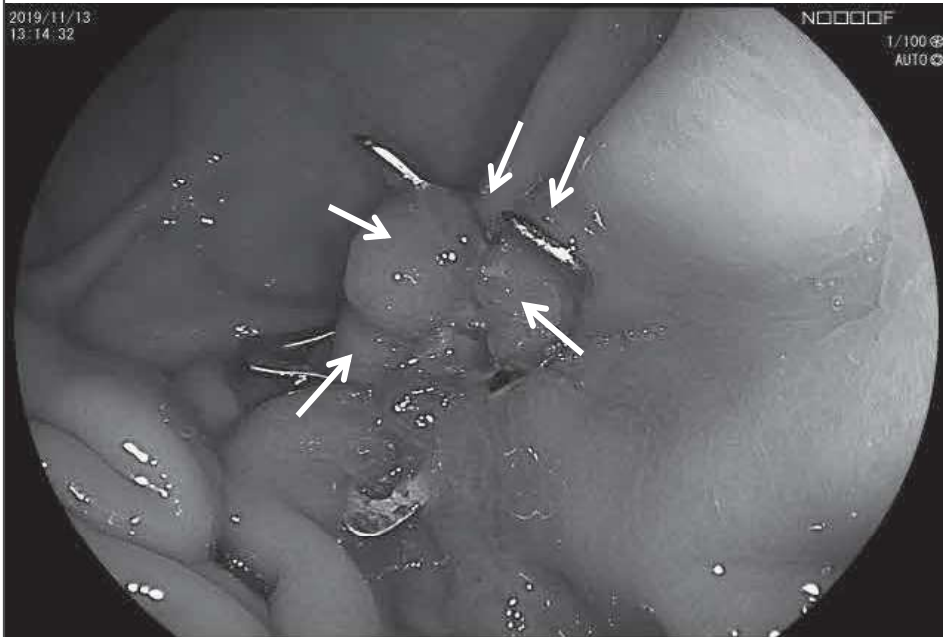


Endoscopic resection with OTSC device (19.10.22)

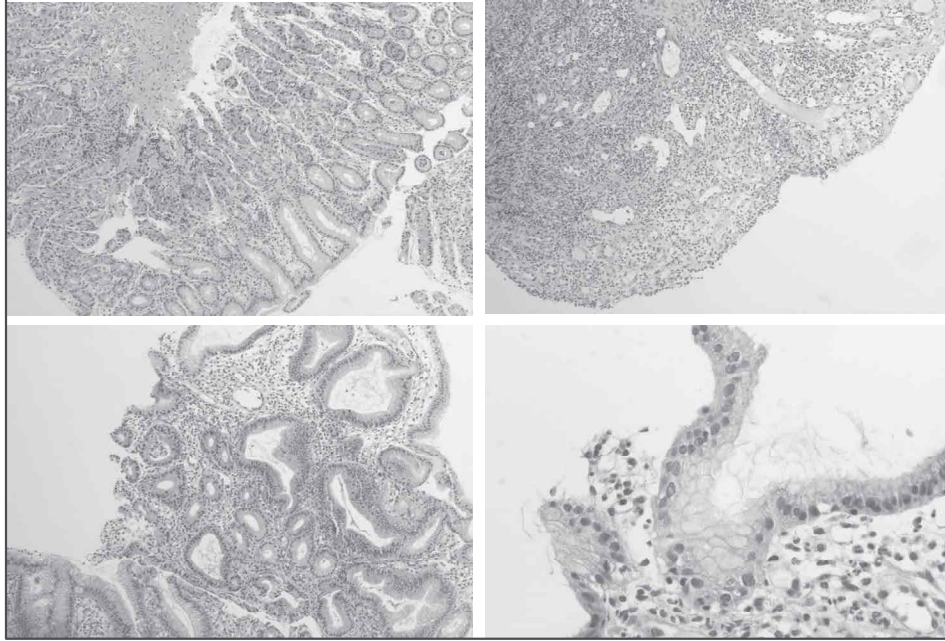


조직검사 : Chronic gastritis

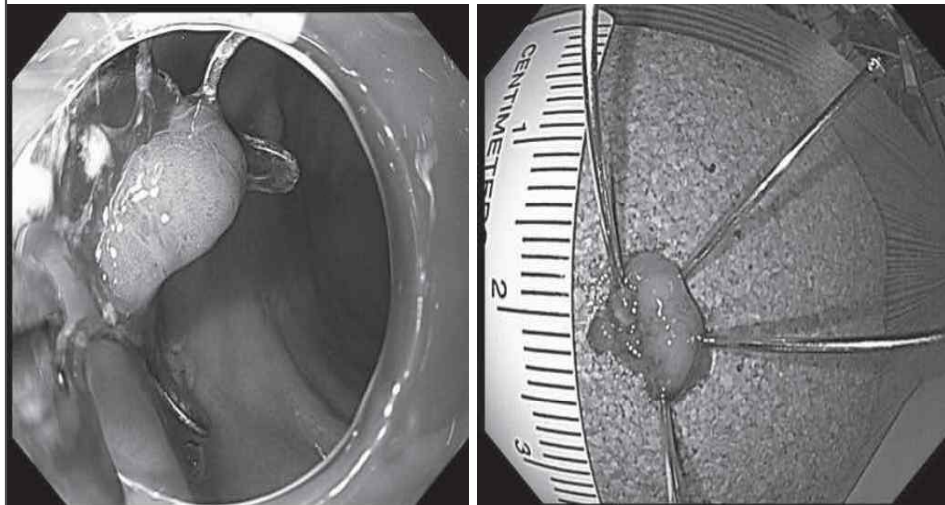
Random needle Bx. (19.11.12)



Random needle Bx. (19.11.12)

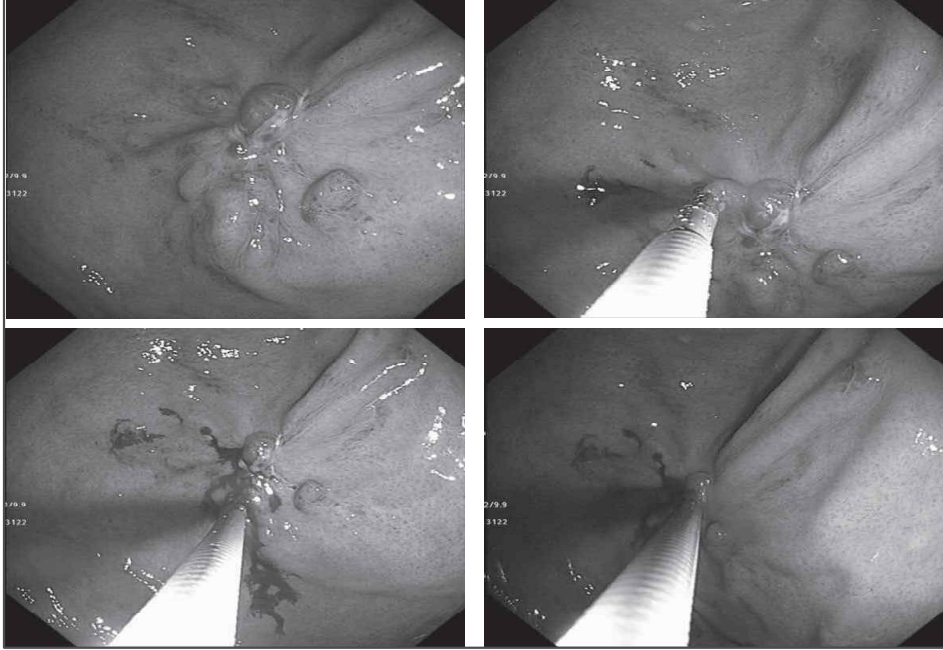

OTSC removal (19.12.02)



조직검사 : Ulcer with chronic gastritis

Random Bx. (19.12.03)



MEMO

MEMO