

Session III

Two Cases of Unresectable Pancreatic Cancer Treated with Neoadjuvant Chemotherapy and Surgical Resection

Gunn Huh, Jung Won Chun, Min Su You, Woo Hyun Paik,
Sang Hyub Lee, Ji Kon Ryu, Yong-Tae Kim

*Division of Gastroenterology, Department of Internal Medicine,
Seoul National University, College of Medicine, Jeonju, Korea*

Case 1

- F/65
- **CC:** RUQ discomfort, weight loss (3MA)
- **Present illness:**
- 3개월 전부터 발생한 우상복부 불편감 및 10 kg의 체중 감소(64 → 54 kg)를 주소로 타원 내원하여 시행한 복부 CT에서 췌장 종괴 발견되어 refer됨.

Case presentation

- **Past medical history**
 - DM/HTN/Tbc/CLD(+/+/-/-)
 - Medication: OHA
 - Op Hx(-)
- **Social history**
 - Smoking/Alcohol (-/-)
- **Family medical history**
 - None
- **Review of systems**
 - No specific findings
- **Physical examination**
 - No specific findings

Laboratory findings

CBC WBC 3,800/uL - Hb **10.7** g/dL – Plt 158,000/uL

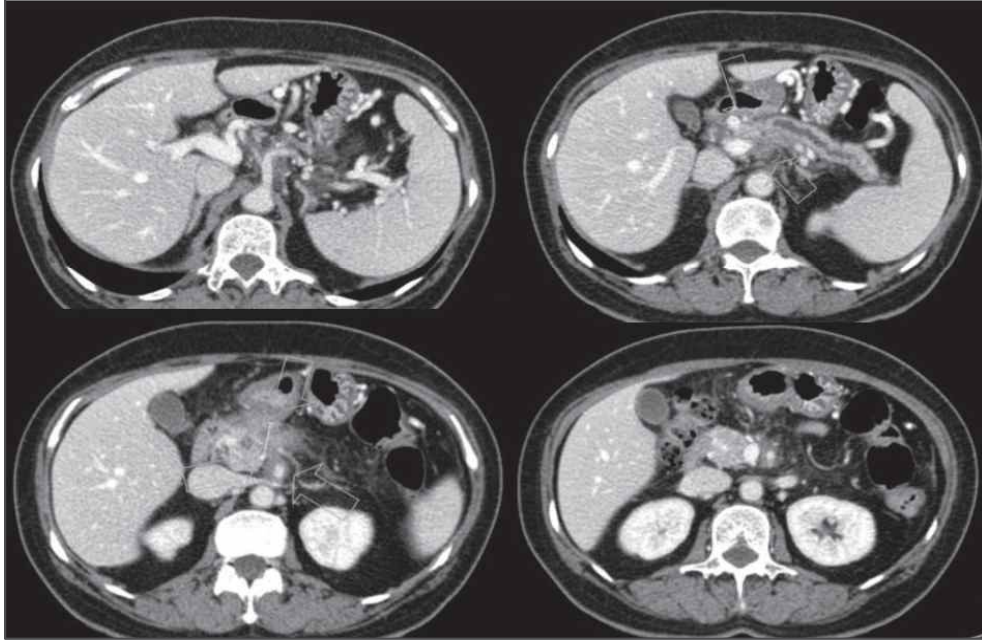
Prot/Alb 6.0/3.6 g/dL, T.bil 0.5 mg/dL, ALP 74 IU/L, AST/ALT 15/24 IU/L

Prothrombine time 80%

CA 19-9 **127 U/mL**, CEA 2.3ng/mL, HbA1c **7.1%**

HBsAg(-), anti-HBs(+), anti-HCV(-)

o/s AP CT (2018-01-26)



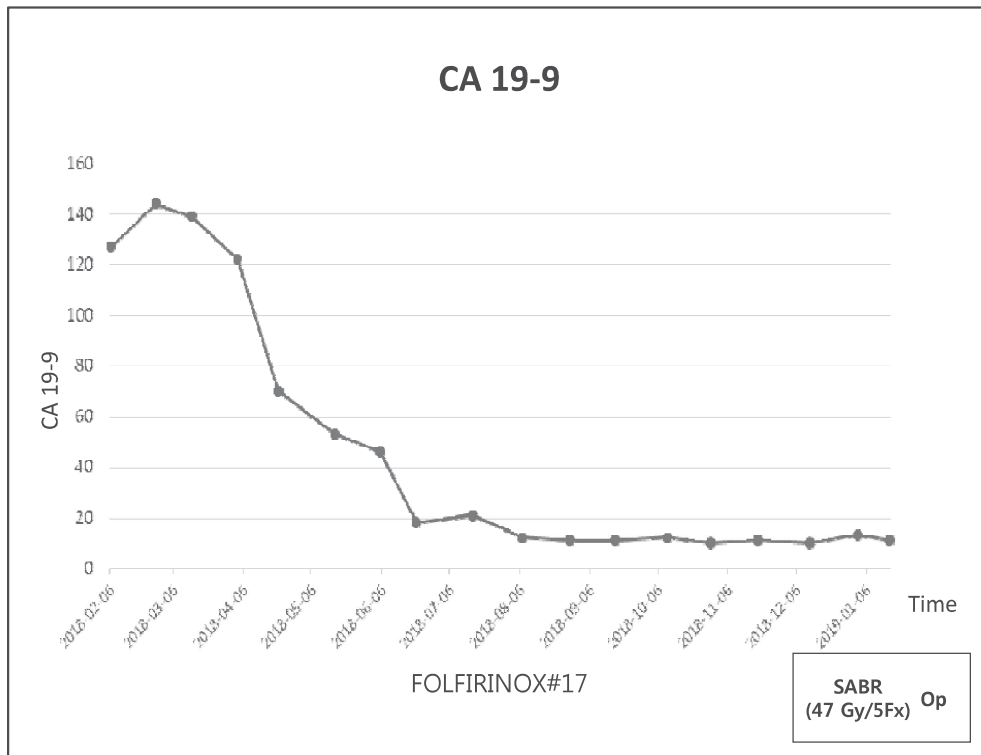
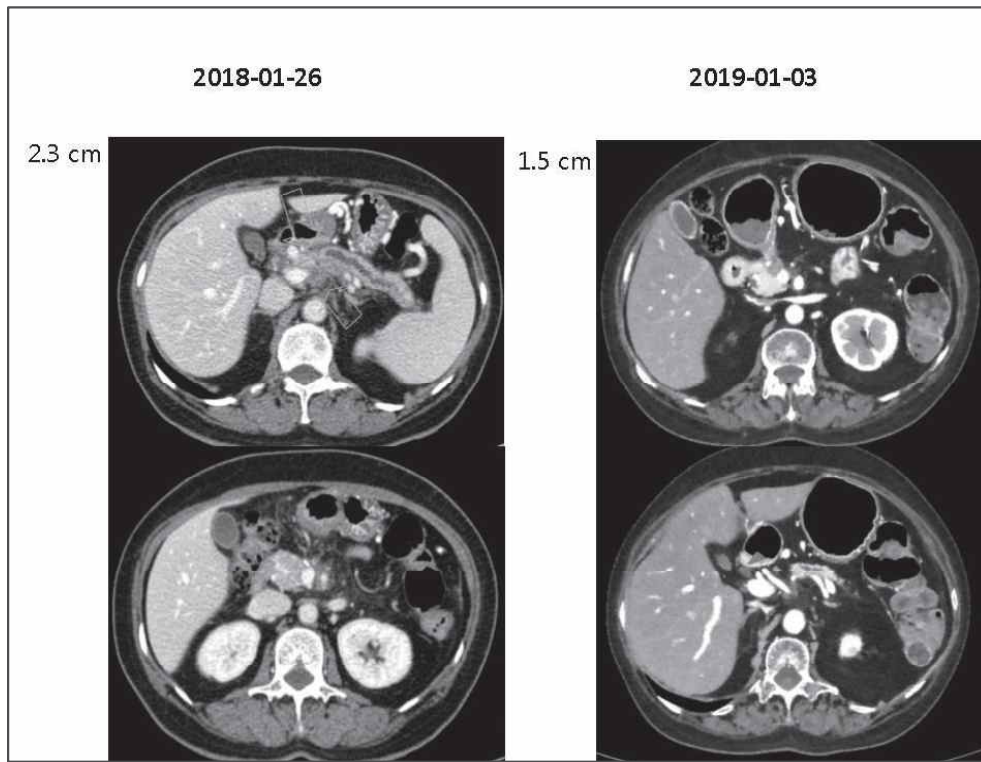
Initial Assessment and Plan

• **Initial assessment**

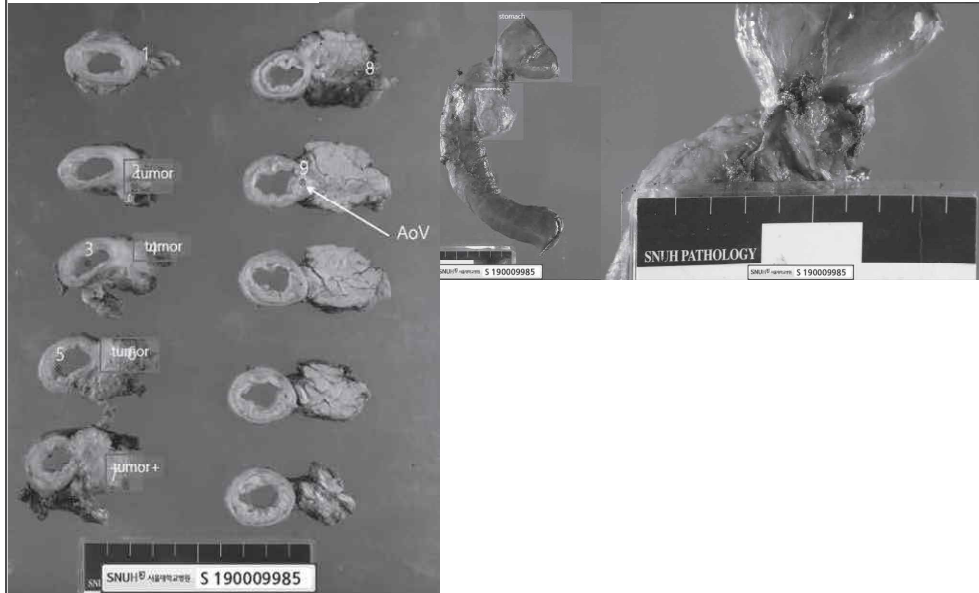
Locally advanced or metastatic pancreatic cancer with SMV/MPV, celiac trunk & SMA encasement and suspicious peritoneal seeding

• **Initial plan**

Palliative chemotherapy (FOLFIRINOX)



Whipple's operation and wedge resection of SMV (2019-02-20)



Whipple's operation and wedge resection of SMV (2019-02-20)

- Ductal adenocarcinoma, moderately differentiated
- Tumor regression grade: CAP grade 2 (partial response)
- **Size: 2.0×1.6×0.7 cm**
- Depth of invasion
 - pancreas: invasion beyond pancreas
 - AoV: no invasion
 - Bile duct: no invasion
 - Duodenum: invasion of submucosa
 - large vessels: invasion adventitia of SMV with clear resection margin
- **Surgical margin: free**
- **Lymph node: 0/15**
- Lymphatic invasion: not identified
- Venous invasion: not identified
- **Perineural invasion: present**
- Pathologic staging(AJCC 8th): **ypT1cN0**

Case 2

- F/71

- CC: Epigastric pain (1MA)

- **Present illness:**

1개월 전부터 발생한 epigastric pain, anorexia로 내원함.

3개월 사이 4 kg의 체중 감소(70 kg->66 kg)가 동반됨.

Case presentation

- **Past medical history**
 - DM/HTN/Tbc/CLD(+/-/-/-)
 - Medication hx(+) OHA
 - NSCLC (adenocarcinoma, pT1aN0), s/p lobectomy('15.7.3)
- **Social history**
 - Smoking/Alcohol (-/-)
- **Family medical history**
 - None
- **Review of systems**
 - No specific findings
- **Physical examination**
 - No specific findings

Laboratory findings

CBC WBC 4,510/uL - Hb 12.1 g/dL - Plt 165,000/uL

Prot/Alb 6.0/3.8 g/dL, Tbil 0.8 mg/dL, ALP 35 IU/L, AST/ALT 15/10 IU/L

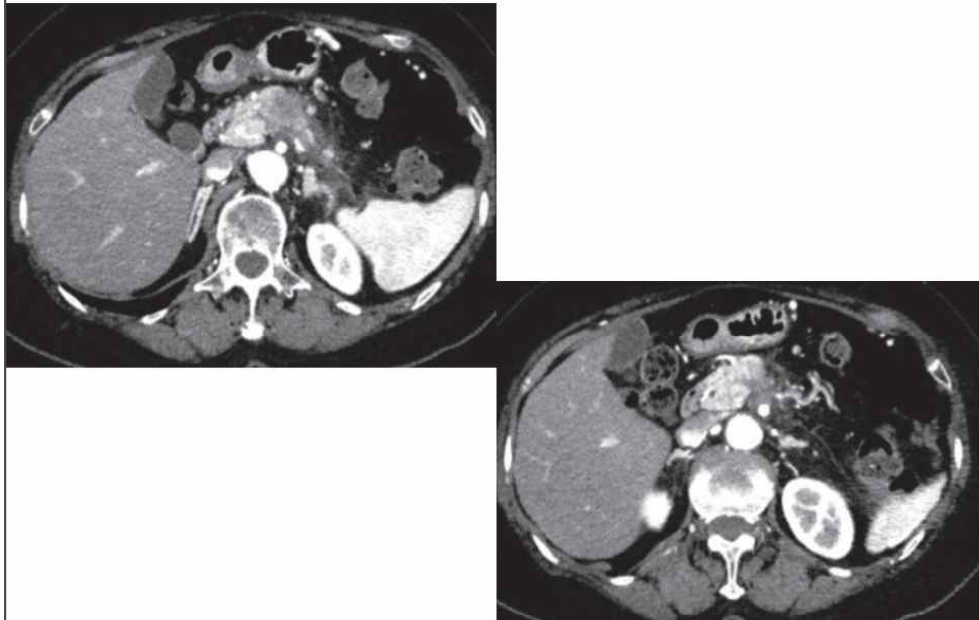PT 100%

CA 19-9 24 U/mL, CEA 1.5 ng/mL

HBsAg(-), anti-HBs(+), anti-HCV(-)

HbA1c 7.5%

(o/s) AP-CT ('18.2.22)



Initial Assessment and Plan

- **Initial assessment**

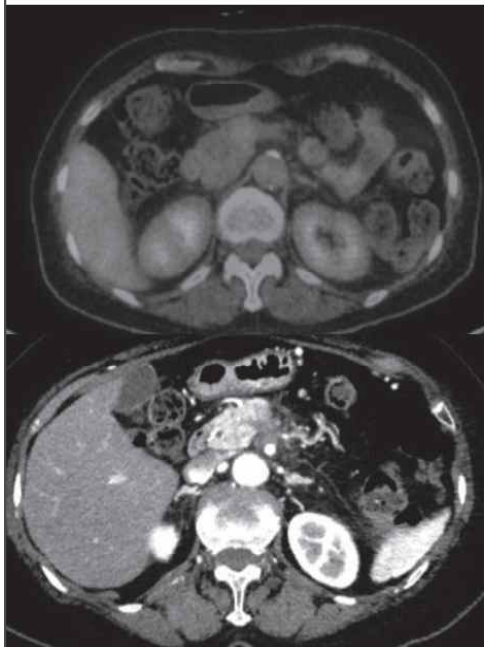Locally advanced pancreatic body cancer with SMA encasement

- **Initial plan**

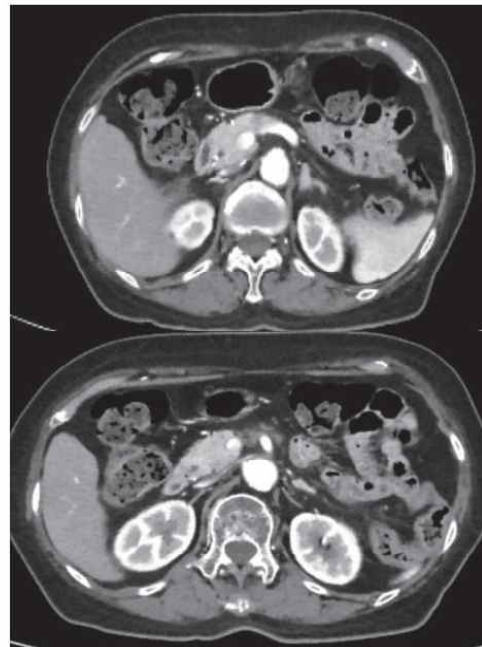
EUS-FNA/B

Palliative chemotherapy (FOLFIRINOX)

PET-CT ('18.08.31)



PB-CT ('18.08.27)



Re-Assessment and Plan

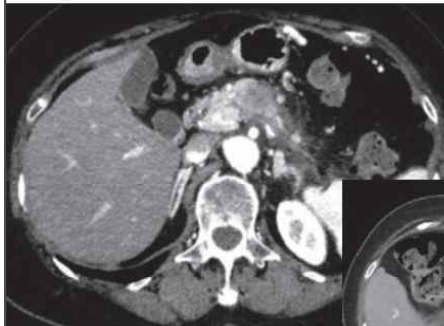
- **Assessment**

Locally advanced pancreatic body cancer with SMA encasement

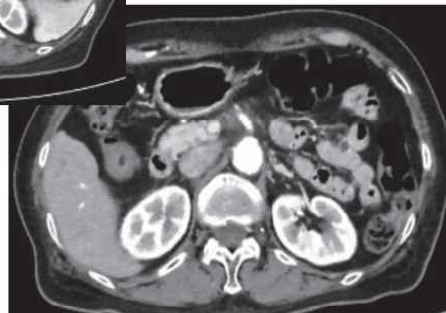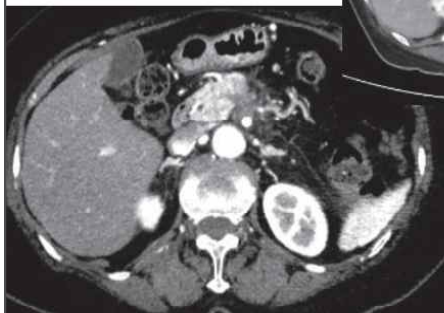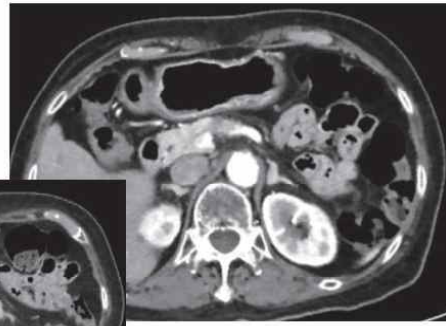
- **Plan**

CCRT with 5-FU#2 ('18.09.27 – '18.11.08) → Operation

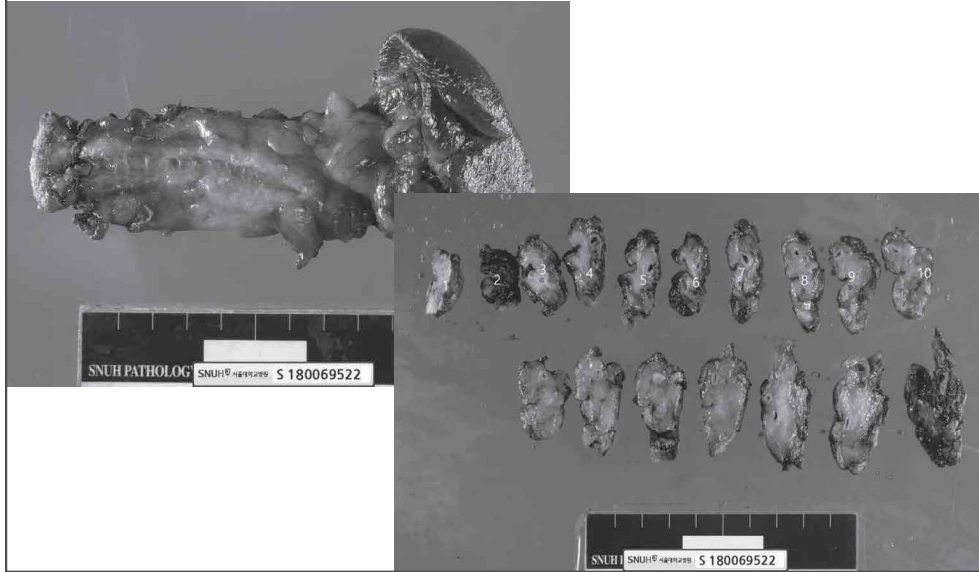
(o/s) AP-CT ('18.2.22)



PB-CT ('18.12.13)



Distal pancreatectomy and splenectomy (2018-12-14)



Distal pancreatectomy and splenectomy (2018-12-14)

- Poorly differentiated carcinoma, residual
 - Tumor regression grade: CAP grade 1, marked response (minimal residual cancer with single cells or small groups of cancer cells)
 - Size: **0.4×0.2** cm
 - Depth of invasion
 - pancreas: limited to pancreas
 - Spleen: no invasion
 - **Surgical margin: free**
 - Lymph node: **0/9**
 - Lymphatic invasion: not identified
 - Venous invasion: not identified
 - Perineural invasion: not identified
- Pathologic staging (AJCC 8th): ypT1aN0